



# Thermal Imaging Report

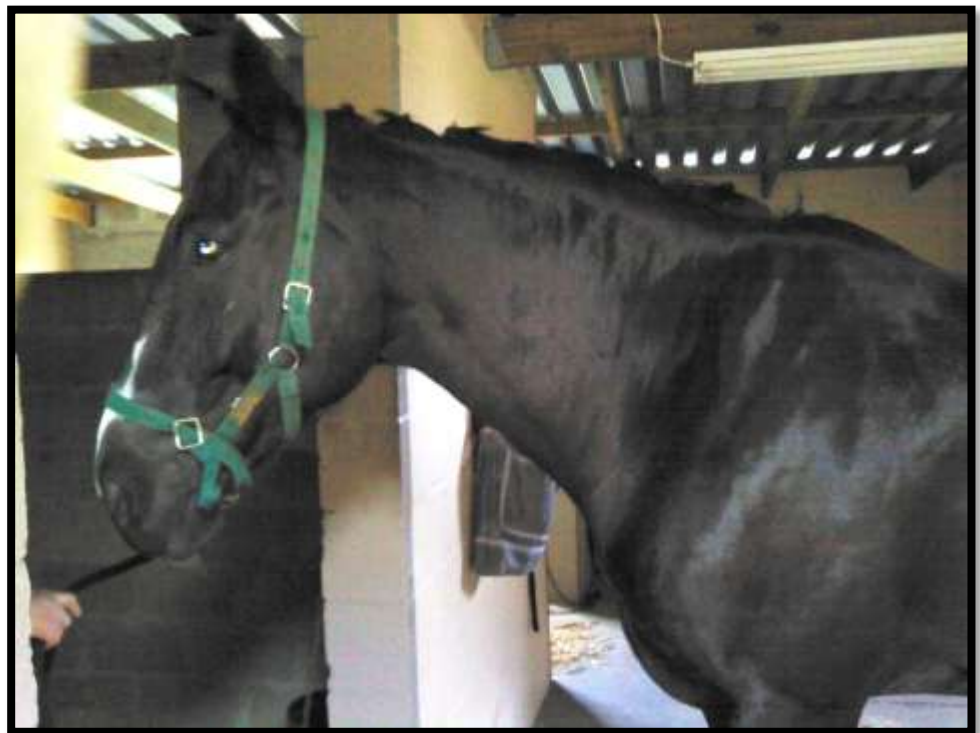## Risky Business



*Thermal Imaging completed by  
a Certified Thermographer  
Authorized with the EquineIR™  
Network.*



*Interpretative results  
completed by Licensed  
Veterinarians in contract with  
Integrated Equine Infrared.*



**Thermal Communications**

6 Brampton Mews, Tiverton Road, Plumstead, 7800

PH: 082 784 3352

FX: 021 797 2173

WEB: [www.thermalcommunications.co.za](http://www.thermalcommunications.co.za)

EMAIL: [report@thermalcommunications.co.za](mailto:report@thermalcommunications.co.za)

September 17, 2013

Lynn Wragg  
Porter Stables, Chrysalis Academy, Tokai  
Cape Town

Dear Lynn Wragg:

EquineIR was recently requested to perform a full body thermal imaging scan of: **Risky Business**

The following photo report was completed by your EquineIR™ Certified Thermographer and all interpretative results were channeled through [interpretir.com](http://interpretir.com) and subsequently formulated and input by a licensed veterinary team member with Integrated Equine Infrared.

The interpretation is intended to aid your regularly-licensed veterinarian in providing a diagnostic or treatment protocol. All follow-up testing and treatments should be conducted and administered by your primary veterinarian. The interpretation provided is based solely on the conditions at the time of survey and the thermal images included in this report. Thermography is a diagnostic tool that measures heat emitted from the surface of the patient. The thermal imaging camera converts infrared energy into a visible image. Emitted heat is related to circulation; as such, the thermal camera can help detect areas of inflammation as well as decreased circulation. Thermal symmetry is key, so we compare one anatomic area with the same area on the other side. The EquineIR™ report is prepared in this manner. It should be understood that correct patient preparation and environment are vital to a successful survey. Your EquineIR™ technician is also a Certified Infrared Thermographer and has been trained in the proper use and the proven techniques of thermal imaging as it is used with horses. However there are certain situations which may reduce the quality of the survey including the improper preparation of the horse prior to technician's arrival. The interpreting veterinarians who review the imagery base their findings and recommendations on information provided, so it is critical that proper care be taken in the preparation process to ensure success.

Thermal imaging is a physiologic modality and should not be relied upon as the sole diagnostic tool. A complete clinical examination by your licensed veterinarian is always recommended for the best diagnosis and follow-up treatment. This Report is not a definitive diagnosis of any illness or disease. It is intended for use only by licensed veterinary professionals to evaluate patient health, diagnose medical conditions, and provide treatment. It is not to be used by individuals for self-diagnosis or self-evaluation, nor for the diagnosis or evaluation of other non-qualified personnel. This report does not replace, nor is intended to replace a complete clinical evaluation by your licensed veterinarian. Under no circumstances will EquineIR™, Integrated Equine Infrared or its affiliates be held responsible for illness, injury, or death to the patient as a result of the information contained herein. This report does not replace, nor is intended to replace a complete clinical evaluation by your licensed veterinarian.

Your EquineIR™ Technician looks forward to working with you in the future. If you would like to set up an ongoing maintenance imaging program for your horse(s), we can arrange this at discounted rates along with multiple horse discounts. Please call our office with any questions as we would love to assist you in your success.

Sincerely,



Dinah Curling,  
*Certified Infrared Thermographer* - Infraspexion Institute

## EQUINE CLIENT INFORMATION

**CLIENT NAME:** Lynn Wragg  
**MAILING ADDRESS:** Porter Stables, Chrysalis Academy, Tokai, Cape Town  
**CLIENT EMAIL:** icaw@telkomsa.net  
**CLIENT PHONE:** 082 495 2751

**HORSES NAME:** Risky Business  
**IMAGE DATE:** 9 September 2013  
**IMAGING TIME:** 15h00

**HORSE AGE:** 7 years  
**HORSE BREED:** Warmblood  
**HORSE PRIMARY USE:** Dressage

## SURVEY INFORMATION

**THERMOGRAPHER:** Dinah Curling  
**INFRARED CERTIFICATION #:** 8341  
**INFRARED CAMERA MODEL:** Flir T335      **CAMERA SERIAL NUMBER:** 48803379  
**NUMBER OF THERMAL IMAGES SUBMITTED:** 30

**WEATHER:** Sunny with light cloud, calm  
**APPROXIMATE TEMPERATURE:** 17 °C  
**IMAGING LOCATION:** Barn aisle

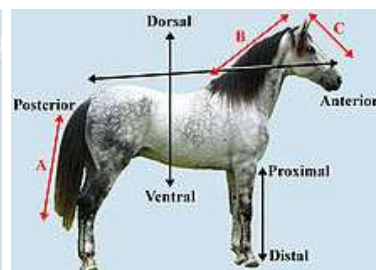
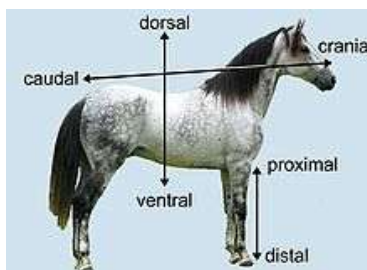
**EXERCISED PRIOR:** Yes    **HOW LONG:** 20 mins    **WHEN:** 40 mins prior  
**TYPE OF EXERCISE:** Lunge in walk and trot only

**BOOTS OR WRAPS ON HORSE?** No      **HOURS SINCE:** Not Applicable  
**FLYSPRAY OR LINIMENTS APPLIED WITHIN 24 HOURS:** No

**REASON FOR SCAN or HISTORY RECEIVED:** General assessment to aid in understanding why the horse has ongoing stiffness and tension issues.

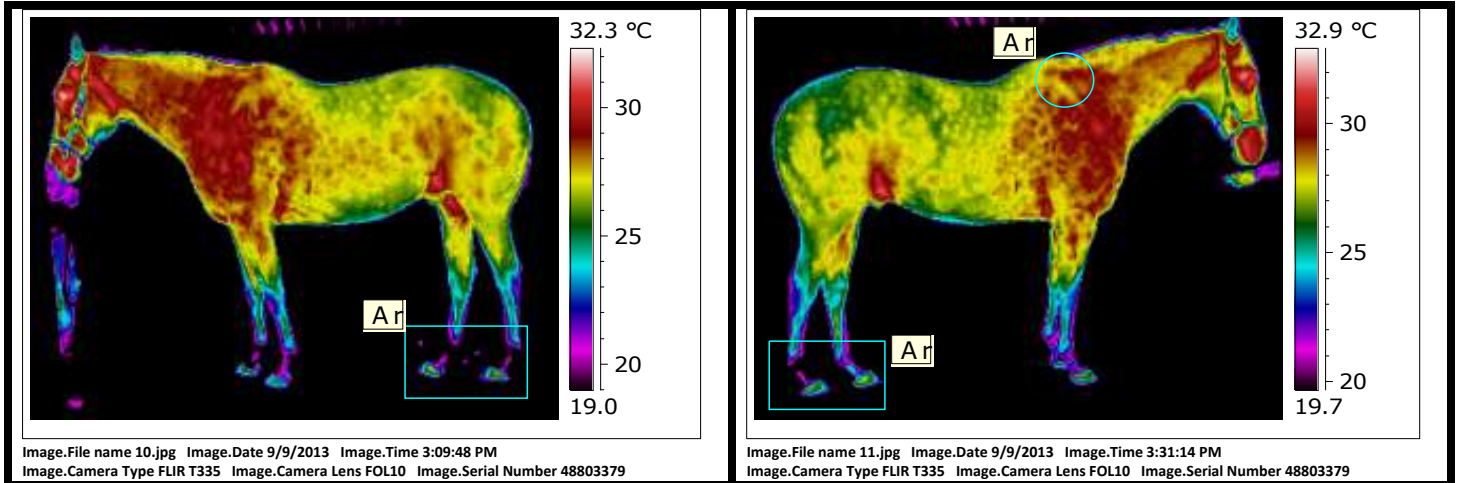
## INTERPRETATION INFORMATION (Completed by Veterinarian)

**INTERPRETATION TYPE:** Full Enhanced Survey  
**DATE OF INTERPRETATION:** 9/17/2013  
**REVIEWING VETERINARIAN:** Dr. Debra K Tibbitts

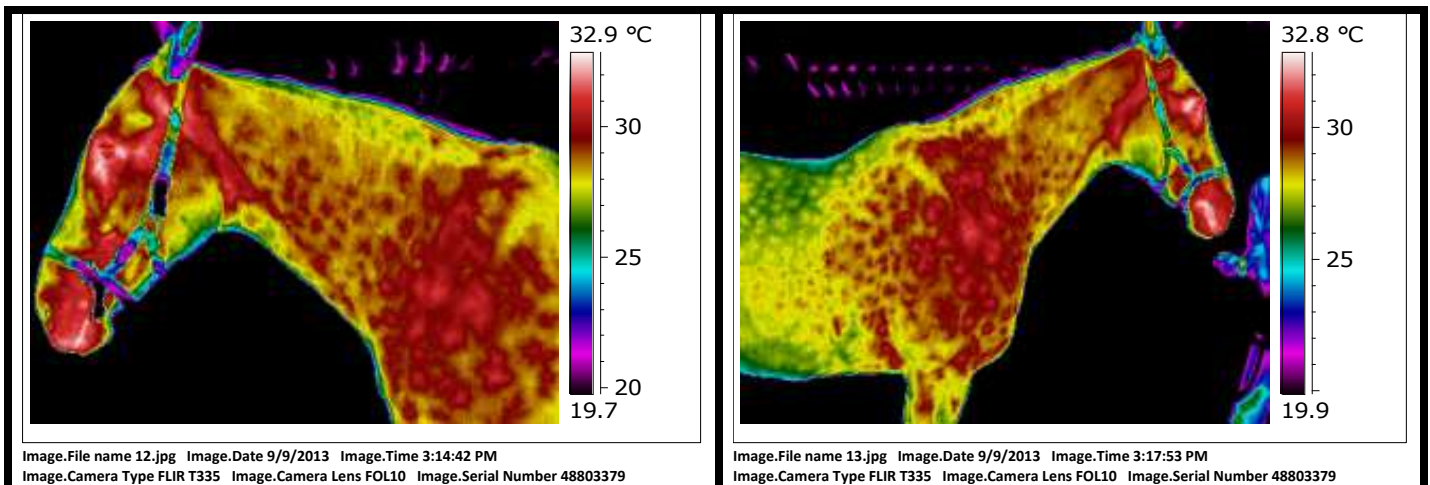


**PATIENT:** Risky Business

**THERMOGRAPHY DATE:** 9 September 2013



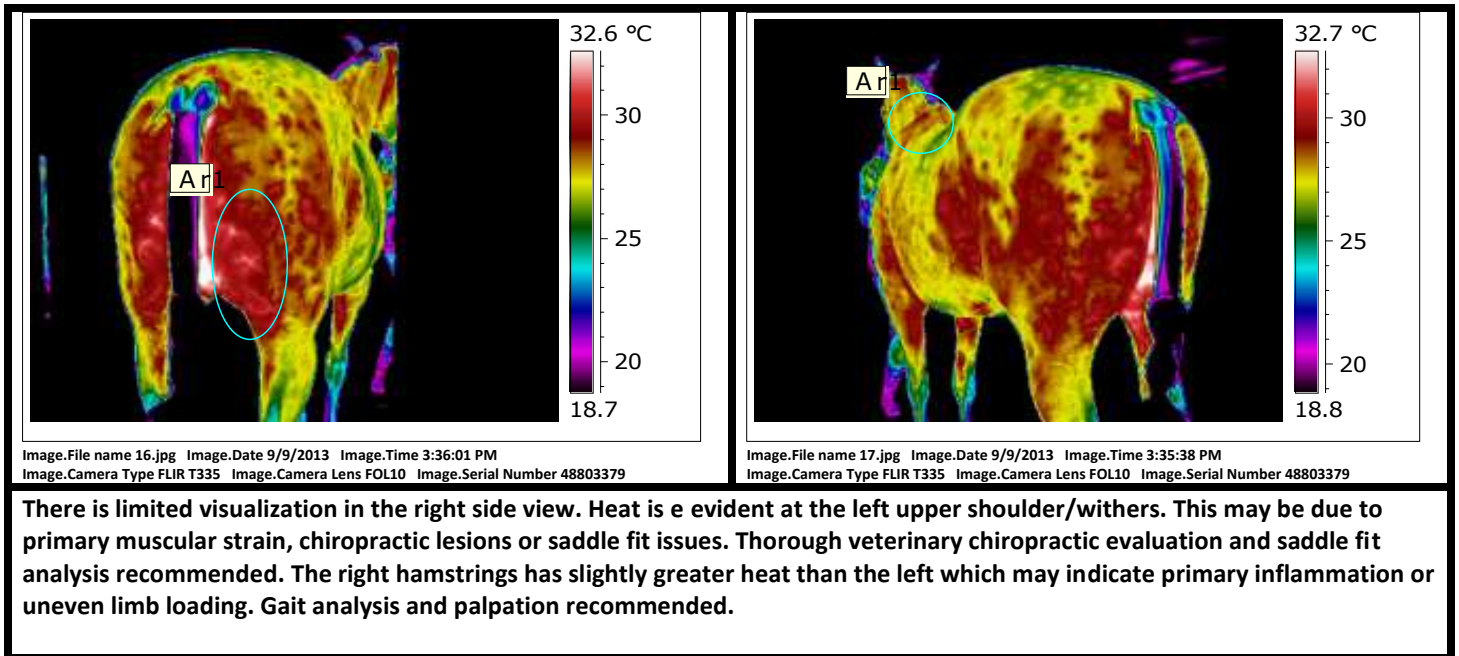
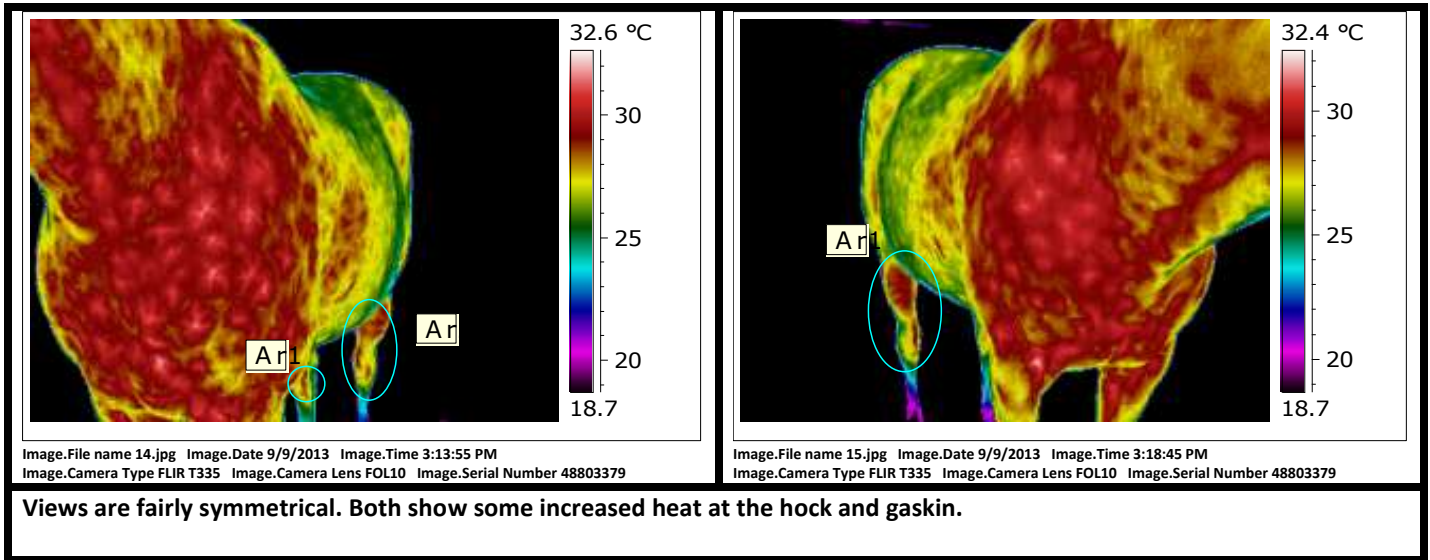
Lateral views have good symmetry – there is artifact present. Comments are based on images submitted. Horse appears down in the fetlocks of both hind limbs and has increased heat in the hind feet, greatest at the heels. This would be consistent with suspensory laxity. The right hindquarter is slightly cooler than the left suggesting uneven limb loading. The right front shoulder/wither area has slightly greater heat than the left which may indicate saddle fit issues, chiropractic issues and/or uneven limb loading.



**NSF: No Significant Findings**

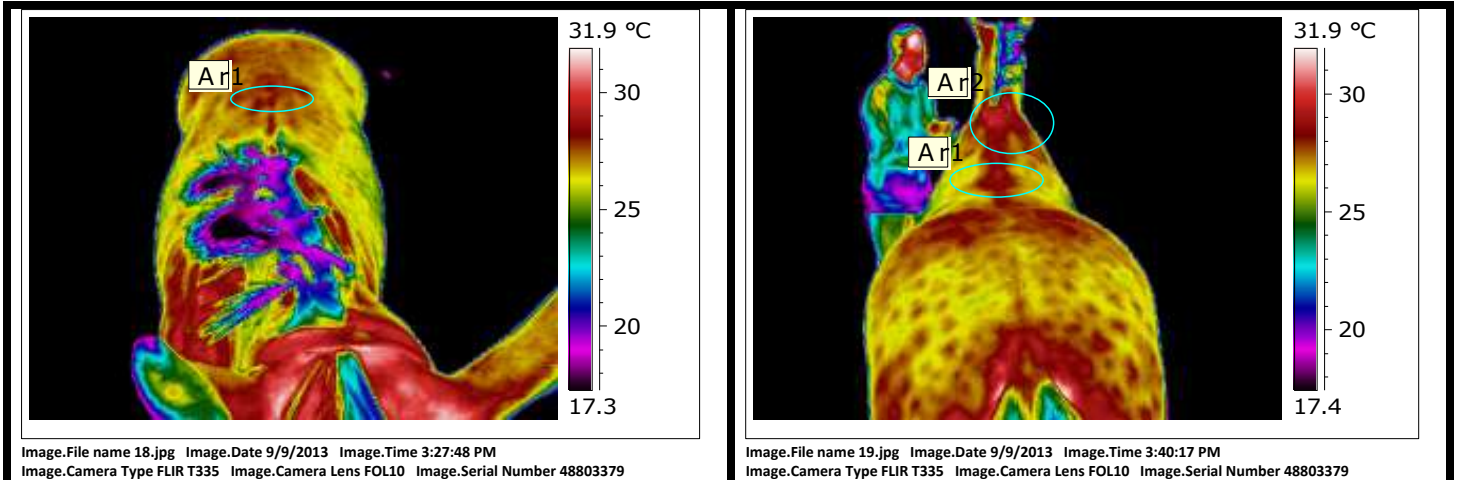
**PATIENT:** Risky Business

**THERMOGRAPHY DATE:** 9 September 2013

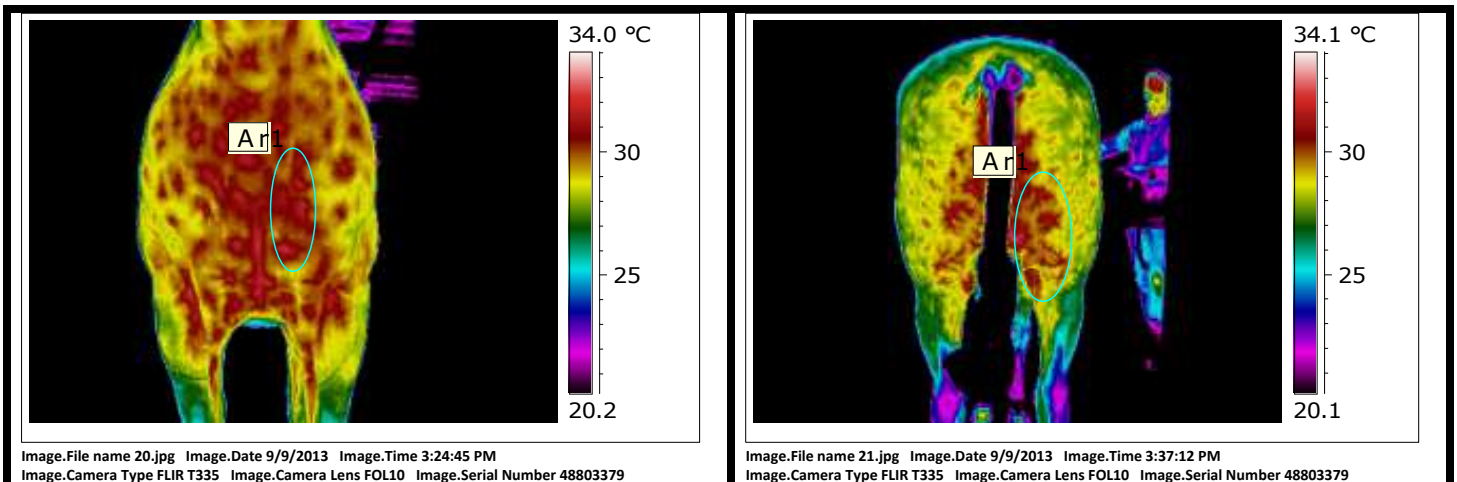


**PATIENT:** Risky Business

**THERMOGRAPHY DATE:** 9 September 2013



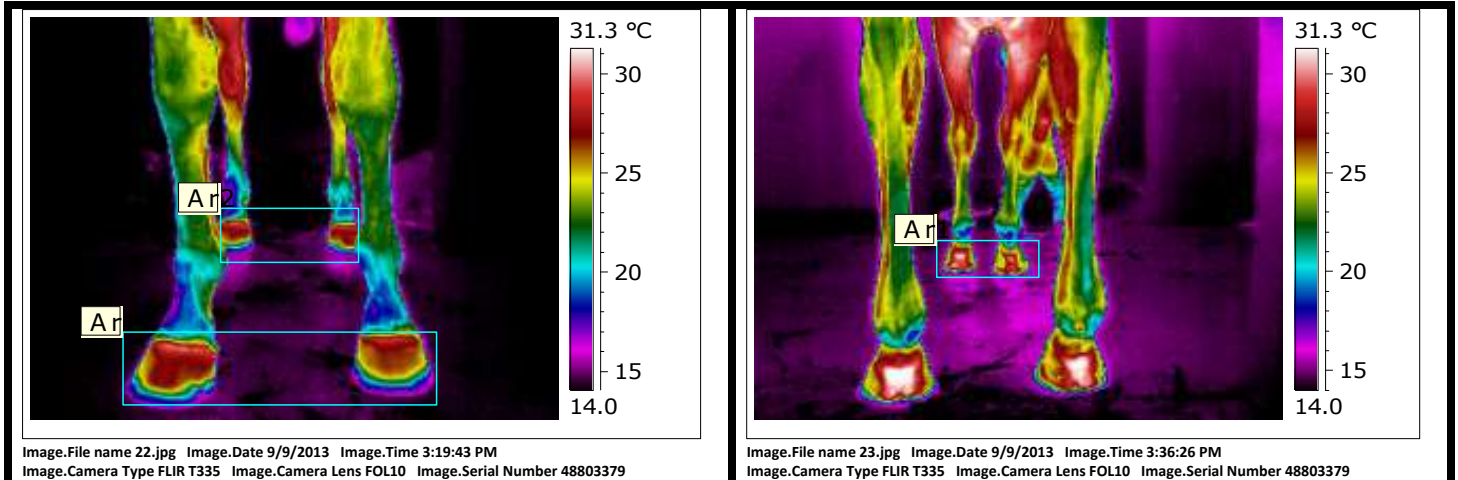
**Increased heat withers and thoracolumbar spine. Some of the increased heat in the spine may be due to conformation, but the area of extension into the paraspinal muscles suggests inflammation from chiropractic lesions, saddle fit issues or kissing spines. Chiropractic evaluation, saddle fit analysis and ultrasound would be valuable for further evaluation.**



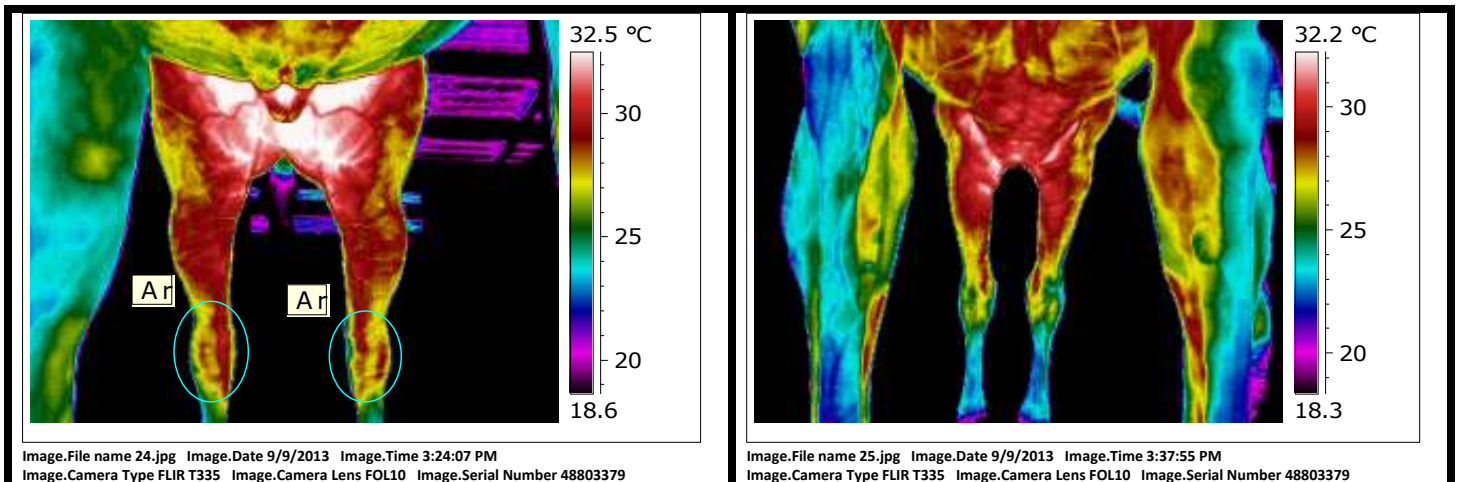
**Slight asymmetry in the chest with heat greater on the right side which may be due to primary muscular inflammation/strain or off-loading of other limb. Palpation recommended.**

**PATIENT:** Risky Business

**THERMOGRAPHY DATE:** 9 September 2013



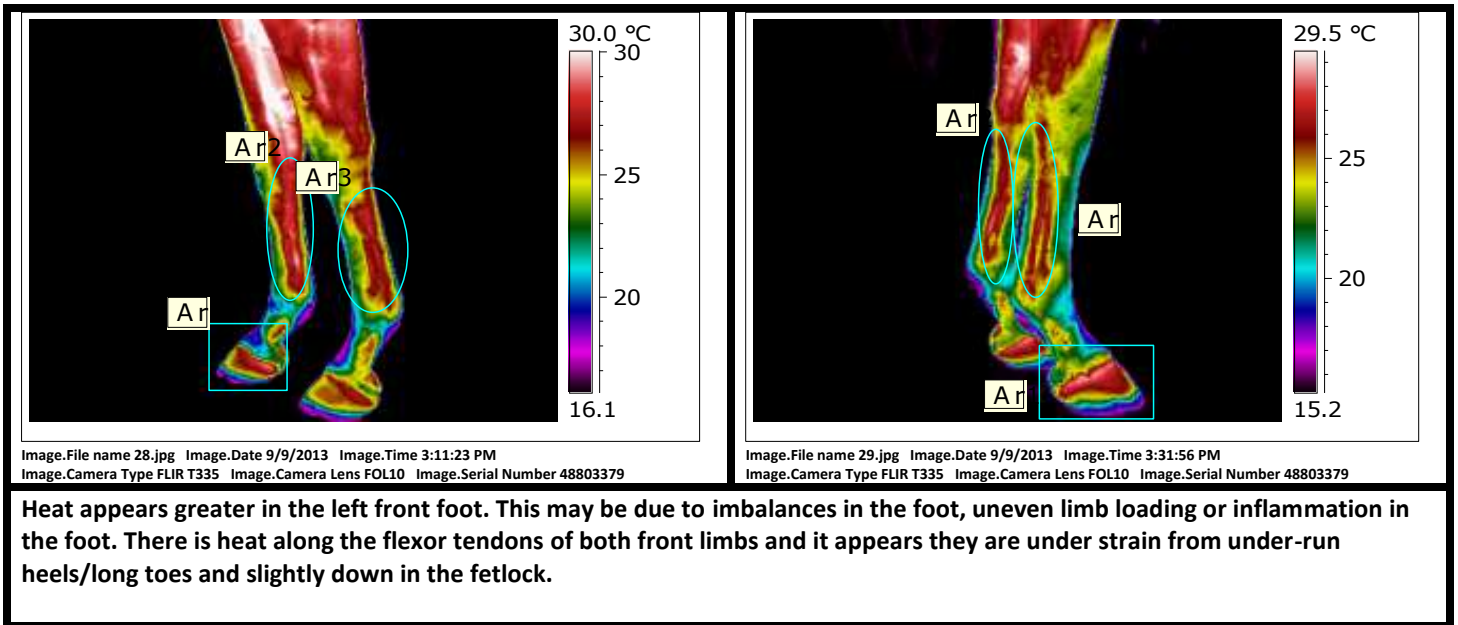
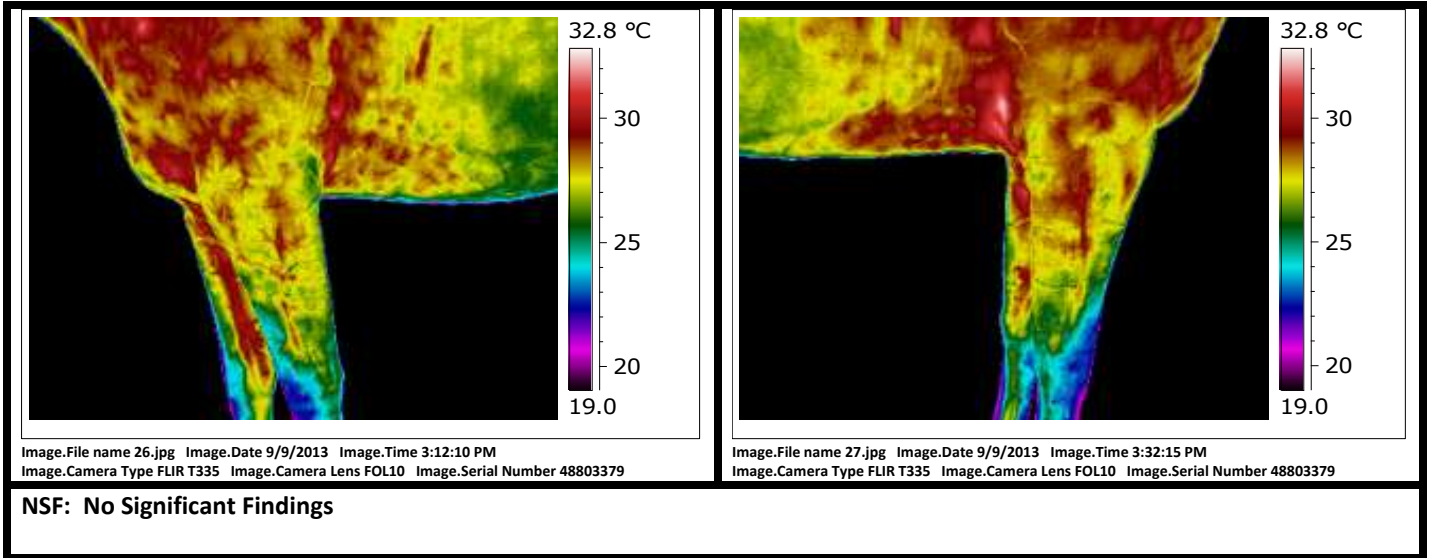
**Heat pattern in the feet suggests stress in the feet. Artifact appears to be present in lower limbs. Heels have increased heat indicating stress and front feet have uneven pressure, with the left front appearing to have greater heat/pressure than the right. This may be due to uneven limb loading or inflammation.**



**Increased heat in both hocks. Gait analysis and flexion testing recommended checking for tarsitis. Front limbs appear fairly symmetrical and though there is slightly greater heat on the right there is also light artifact seen on the right front limb.**

**PATIENT:** Risky Business

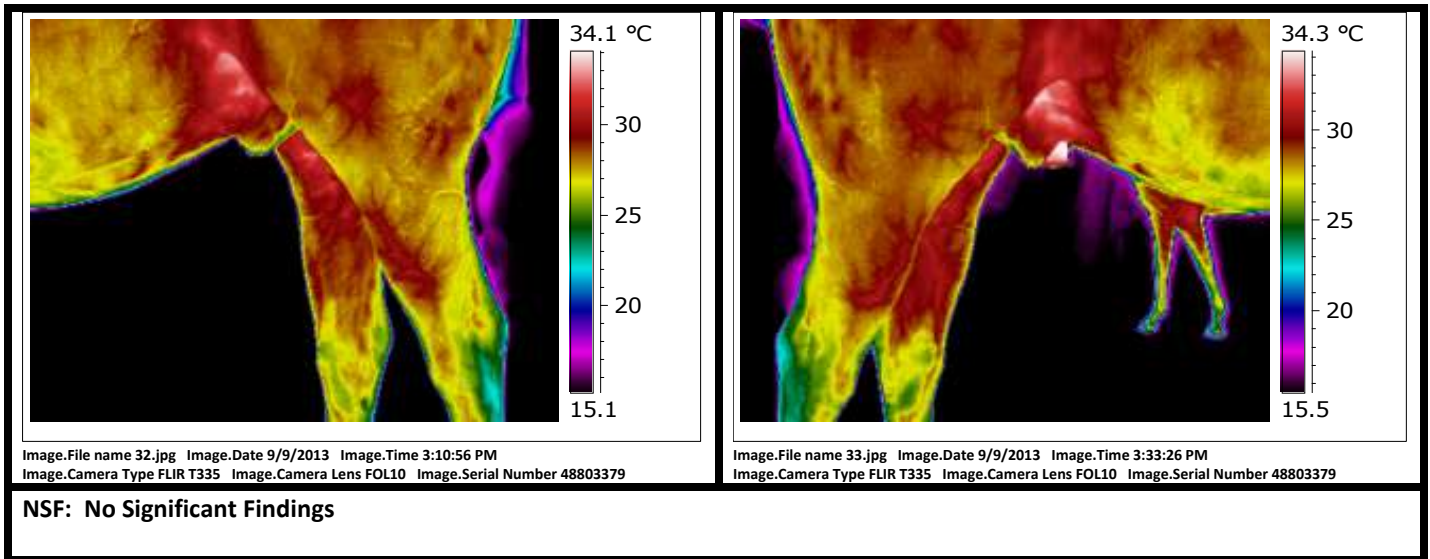
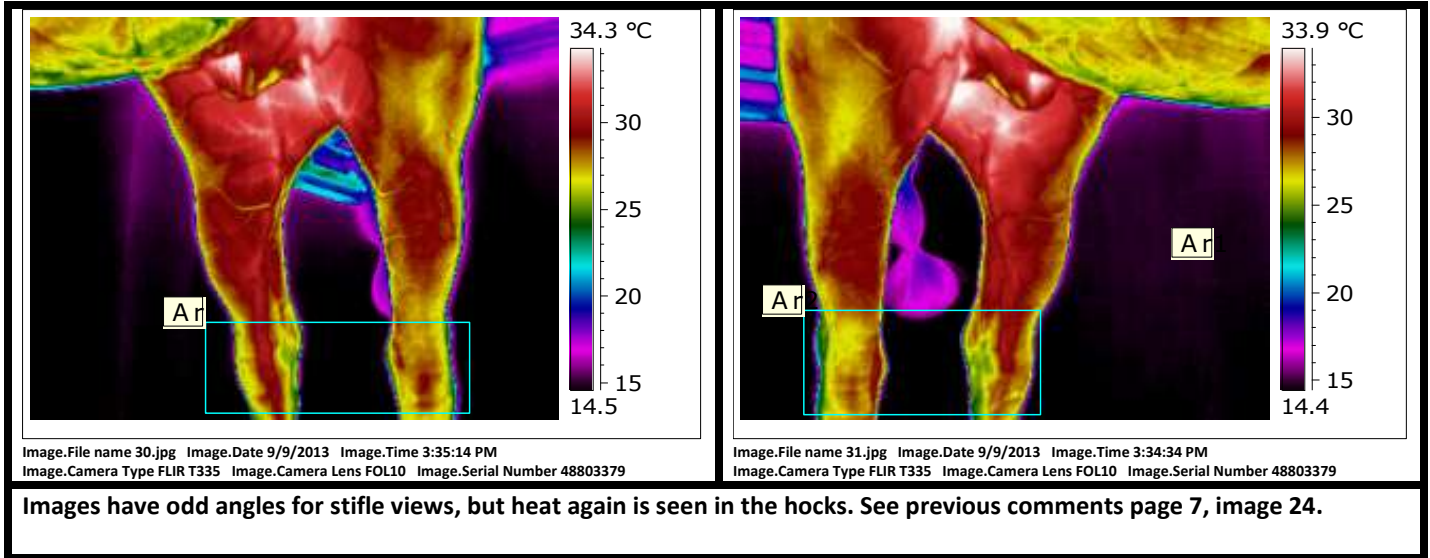
**THERMOGRAPHY DATE:** 9 September 2013





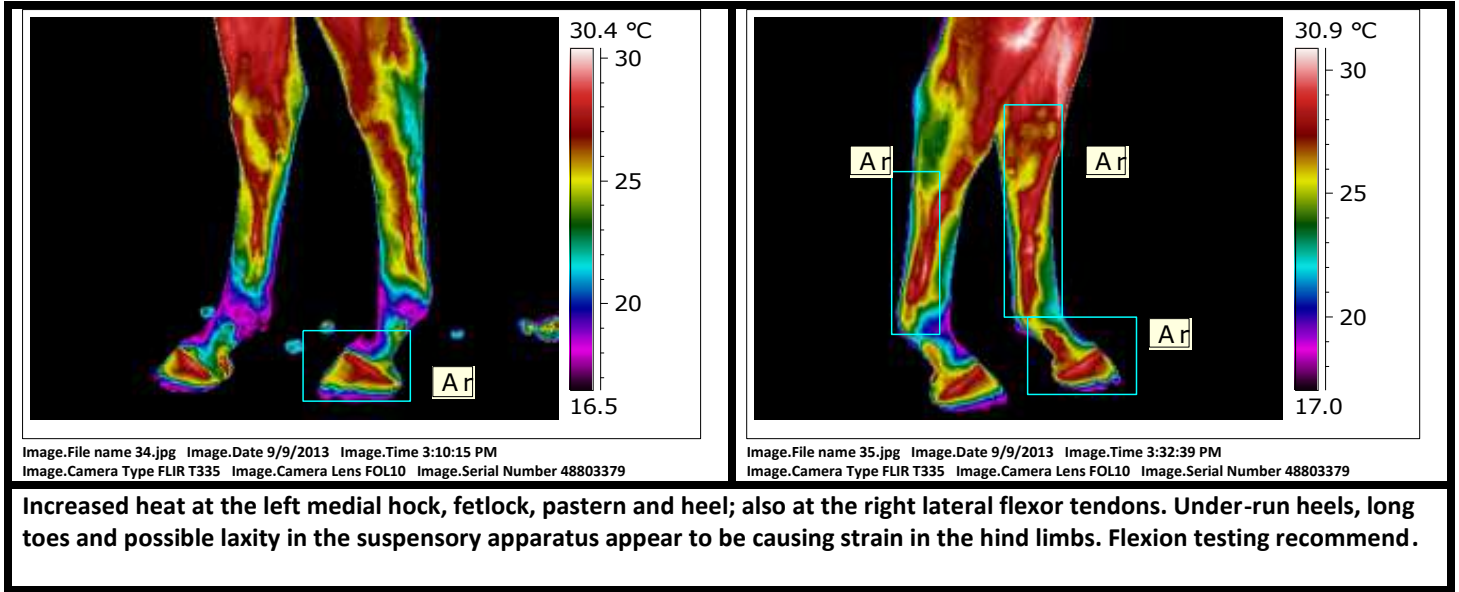
**PATIENT:** Risky Business

**THERMOGRAPHY DATE:** 9 September 2013



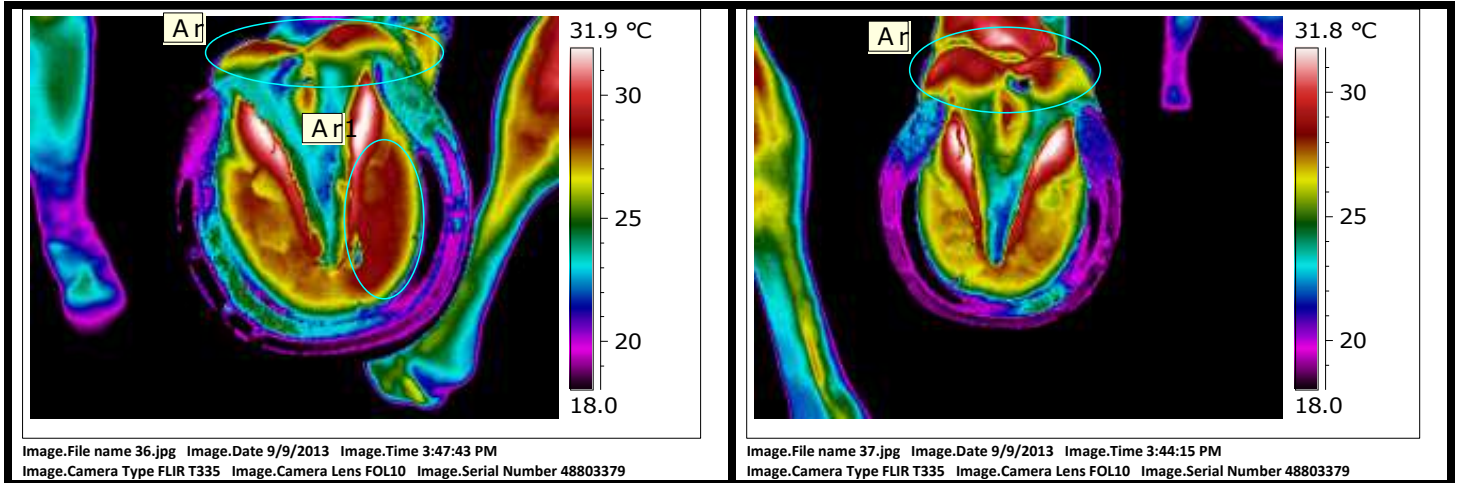
**PATIENT:** Risky Business

**THERMOGRAPHY DATE:** 9 September 2013

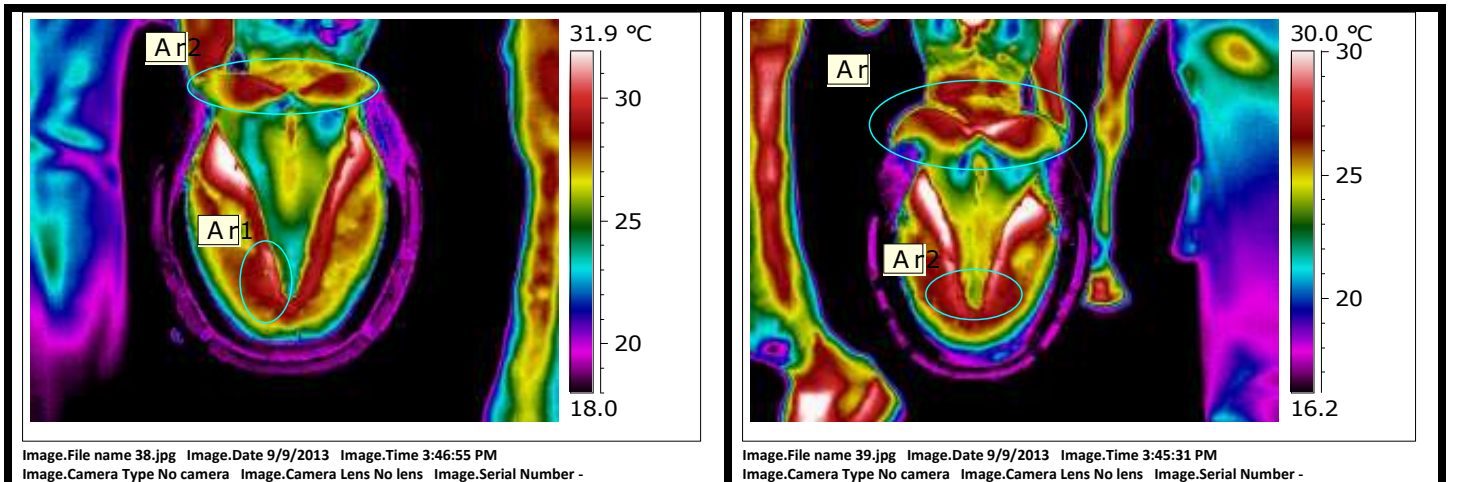


**PATIENT:** Risky Business

**THERMOGRAPHY DATE:** 9 September 2013



There is uneven pressure at the heels on both front feet with pressure greater on the left front medial heel and right front medial heel. Left front shoe appears to be set crooked. There is increased heat/pressure medial quarter left front foot and slightly greater at the later toe quarter right front foot. This may be due to uneven limb loading or imbalances in the foot.



Uneven heel pressure both hind feet and left hind shoe appears to be set crooked. Slight increase heat at toe of both hind feet.

**PATIENT:** Risky Business

**THERMOGRAPHY DATE:** 9 September 2013

**SUMMARY AND RECOMMENDATIONS:** Risky Business is a handsome horse and sounds like he receives excellent care, but there are some concerns based on the images submitted.

Several images have light artifact and possible moisture artifact and proper tuning was difficult on some. Still there is much to be gleaned and comments are based on images presented.

There is increased heat in the withers and spine indicating that there are possibly still saddle fit issues and/or chiropractic issues present. A saddle fit scan/analysis is highly recommended based on the history of repeated saddle adjustments. The history of stiffness and reluctance to be saddled could correlate with saddle fit issues and/or gastric/colonic ulcers. History also shows horse on medication but certain types of ulcers can be very resistant and require a combination of medications to resolve. Endoscopy recommended for further evaluation of the stomach. The increased focal heat in the thoracolumbar spine may also be due to chiropractic lesions or kissing spines. Veterinary chiropractic evaluation and possible ultrasonic imaging of the area recommended.

There is slight asymmetry in the chest and semitendinosus which may be due to uneven limb loading or mild local inflammation or environmental artifact. Palpation recommended. It does appear to be consistent with the history of diagonal tension.

There is heat seen in both hocks, slightly greater on the left which may indicate tarsitis. Gait analysis and flexion testing recommended for further evaluation. Radiographs may also be warranted at that time.

There is heat patterning in the feet and tendons that suggest strain and the digital images show lack of support under the fetlocks and suspensory apparatus. This maybe e partially due to conformation/inherent tendon/ligament laxity and extra support via trimming and shoeing may be required. The feet have increased heat at the heels, uneven pressure medial to lateral across the heels, uneven sole pressure and shoe placement. A farrier consultation may be helpful with our farrier consultant, Mike DeLeonardo of DeLeonardo Farrier Service. This may be set up by phoning 831-442-9154.

### **Thank You!**

Reviewing Veterinarian: Debra K Tibbitts, DVM, CVCP, EDO, CVA, CIT

