



# Thermal Imaging Report

## Quarter Champ



*Thermal Imaging completed by  
a Certified Thermographer  
Authorized with the EquineIR™  
Network.*



*Interpretative results  
completed by Licensed  
Veterinarians in contract with  
Integrated Equine Infrared.*



**Arnt Myrvoll AS**

Kjelsåsveien 174

0884 Oslo

Norge

Tel: +47 91717419/+47 95804696

Web: [www.arntmyrvoll.no](http://www.arntmyrvoll.no)

e-mail: [arntmyrvoll@online.no](mailto:arntmyrvoll@online.no)

WEB: [www.equineir.com](http://www.equineir.com)

EMAIL: [info@equineir.com](mailto:info@equineir.com)



Phone: +47 91717419  
Email: arntmyrvoll@online.no  
Web: www.arntmyrvoll.no  
www.equineir.com

**PATIENT:** Quarter Champ

**THERMOGRAPHY DATE:** 30.12.2013

**IMAGING TIME:** 11.00

January 7, 2014

Hege Tyldum  
Haugane 47  
3409 Tranby

Dear Hege Tyldum:

EquineIR was recently requested to perform a full body thermal imaging scan of: **Quarter Champ**

The following photo report was completed by your EquineIR™ Certified Thermographer and all interpretative results were channeled through interpretir.com and subsequently formulated and input by a licensed veterinary team member with Integrated Equine Infrared.

The interpretation is intended to aid your state-licensed veterinarian in providing a diagnostic or treatment protocol. All follow-up testing and treatments should be conducted and administered by your primary veterinarian. The interpretation provided is based solely on the conditions at the time of survey and the thermal images included in this report. Thermography is a diagnostic tool that measures heat emitted from the surface of the patient. The thermal imaging camera converts infrared energy into a visible image. Emitted heat is related to circulation; as such, the thermal camera can help detect areas of inflammation as well as decreased circulation. Thermal symmetry is key, so you compare one anatomic area with the same area on the other side. The EquineIR™ report is prepared in this manner. It should be understood that correct patient preparation and environment are vital to a successful survey. Your EquineIR™ technician is also a Certified Infrared Thermographer and has been trained in the proper use and the proven techniques of thermal imaging as it is used with horses. There are however certain situations which may reduce the quality of the survey including the improper preparation of the horse prior to technician's arrival. The interpreting veterinarians who review the imagery base their findings and recommendations on information provided, so it is critical that proper care be taken in the preparation process to ensure success.

Thermal imaging is a physiologic modality and should not be relied upon as the sole diagnostic tool. A complete clinical examination by your state-licensed veterinarian is always recommended for the best diagnosis and follow-up treatment. This Report is not a definitive diagnosis of any illness or disease. It is intended for use only by licensed veterinary professionals to evaluate patient health, diagnose medical conditions, and provide treatment. It is not to be used by individuals for self-diagnosis or self-evaluation, nor for the diagnosis or evaluation of other non-qualified personnel. This report does not replace, nor is intended to replace a complete clinical evaluation by your state-licensed veterinarian. Under no circumstances will EquineIR™, Integrated Equine Infrared or its affiliates be held responsible for illness, injury, or death to the patient as a result of the information contained herein. This report does not replace, nor is intended to replace a complete clinical evaluation.

Your EquineIR™ Technician looks forward to working with you in the future. If you would like to set up an ongoing maintenance imaging program for your horse(s), we can arrange this at discounted rates along with multiple horse discounts. Please call our office with any questions as we would love to assist you in your success.

Sincerely,

*Anne M. Myrvoll*

Thermographer, *Certified Infrared Thermographer*



Phone: +47 91717419  
 Email: arntmyrvoll@online.no  
 Web: www.arntmyrvoll.no  
 www.equineir.com

**PATIENT:** Quarter Champ

**THERMOGRAPHY DATE:** 30.12.2013

**IMAGING TIME:** 11.00

## EQUINE CLIENT INFORMATION

**CLIENT NAME:** Hege Tyldum  
**MAILING ADDRESS:** Haugane 47, 3409 Tranby  
**CLIENT EMAIL:** hegety@lifi.nogh  
**CLIENT PHONE:** +47 91616736

**HORSE AGE:** 5  
**HORSE BREED:** Hanoverian  
**HORSE PRIMARY USE:** Dressage/hobby

## SURVEY INFORMATION

**THERMOGRAPHER:** Anne M. Myrvoll  
**INFRARED CERTIFICATION #:** NO.2011NO47N003  
**INFRARED CAMERA MODEL:** T335      **CAMERA SERIAL NUMBER:** 48804121  
**NUMBER OF THERMAL IMAGES SUBMITTED:** 30

**WEATHER:** Sunny  
**APPROXIMATE TEMPERATURE:** -4 °C  
**IMAGING LOCATION:** Barn aisle

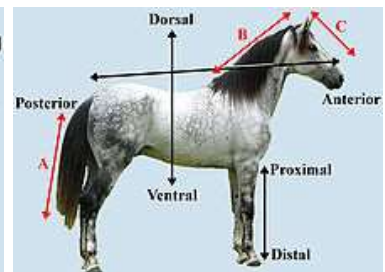
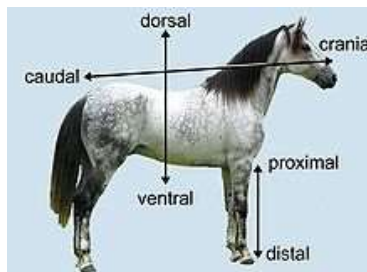
**EXERCISED PRIOR:** Yes    **HOW LONG:** 40 min    **WHEN:** 10.30  
**TYPE OF EXERCISE:** Walk and trot in lounge. Horse has just been on stall rest, so this was max training for him. He was still too cold.

**BOOTS OR WRAPS ON HORSE?** Yes, within 12 hours      **HOURS SINCE:** 5-6  
**FLYSpray OR LINIMENTS APPLIED WITHIN 24 HOURS:** No

**REASON FOR SCAN or HISTORY RECEIVED:** NB, horse wore blanket until 09. Owner bought the horse 1.5 months ago and wants to be sure he is healthy. They suspect there is something wrong because he has been on and off lame in his l.f when ridden and he sticks his tongue out sometimes during work. He also windsucks/cribs. He had narrow hooves and frogs after poor shoeing, but his new farrier has started working on this. **NOTE FROM IMAGER:** We did a static saddle fit after imaging, and his saddle had a correct angle, but was too narrow (too high front/too low back), with a narrow channel placing rider in a chair seat. He was sore and had a "plate" in the back of the ssa. A small roach is visible.

## INTERPRETATION INFORMATION (Completed by Veterinarian)

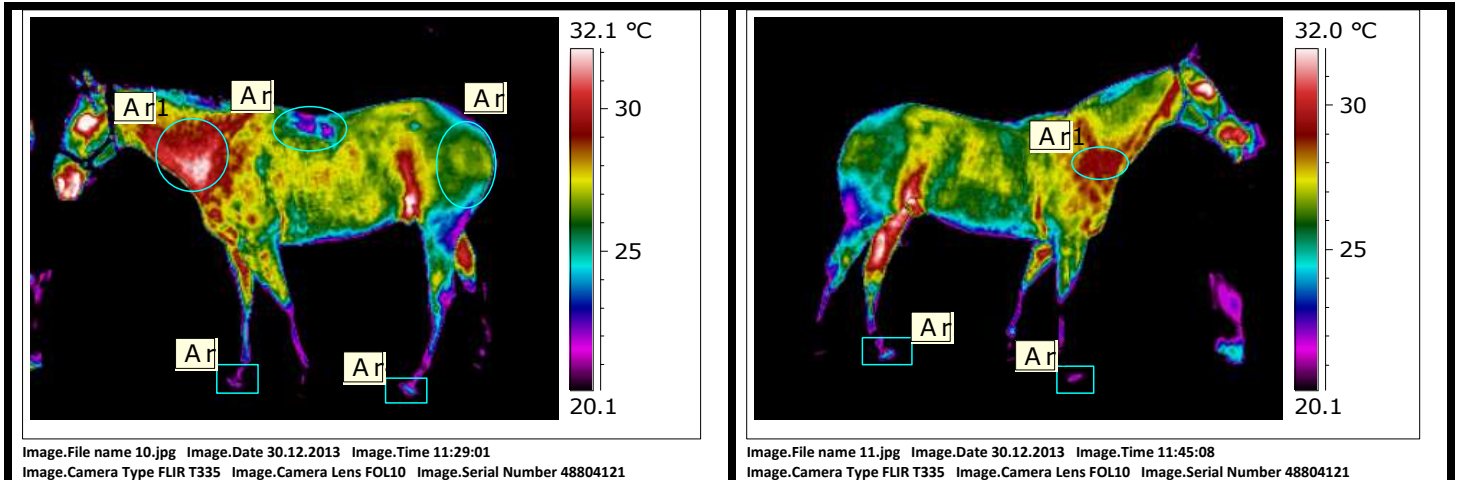
**INTERPRETATION TYPE:** Full Enhanced Survey  
**DATE OF INTERPRETATION:** 1/6/2014  
**REVIEWING VETERINARIAN:** Dr. Debra K Tibbitts



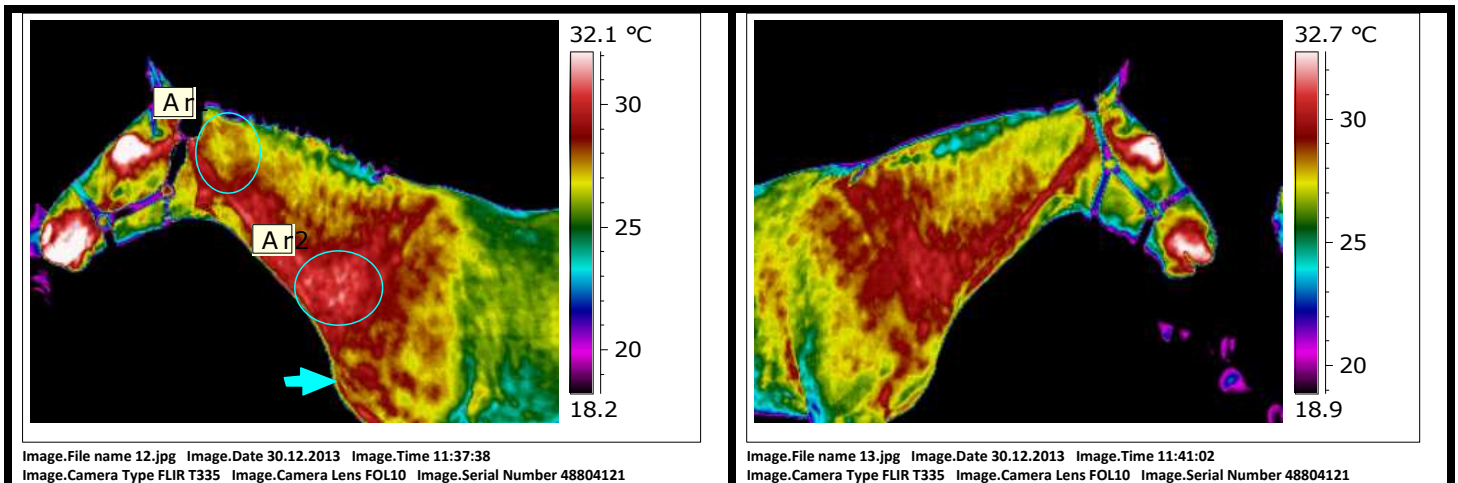
PATIENT: Quarter Champ

THERMOGRAPHY DATE: 30.12.2013

IMAGING TIME: 11.00



Some asymmetry seen on lateral views. Left lower cervical and shoulder areas have greater heat than the right, with slight increase seen in lower cervical area on the right. Musculoskeletal inflammation, chiropractic lesions or uneven limb loading present. Palpation including motion palpation and gait analysis recommended for further evaluation. The right front and left hind feet have greater heat than the left front and right hind. The asymmetry in the feet may be due to off-loading or primary inflammation. Gait and postural analysis and long with hoof tester evaluation recommended. There is asymmetry in the biceps femoris muscle with heat greater on the left – palpation recommended to check for primary inflammation. The cooler area seen in the mid-back may be artifact but palpation is recommended to rule out inflammation.

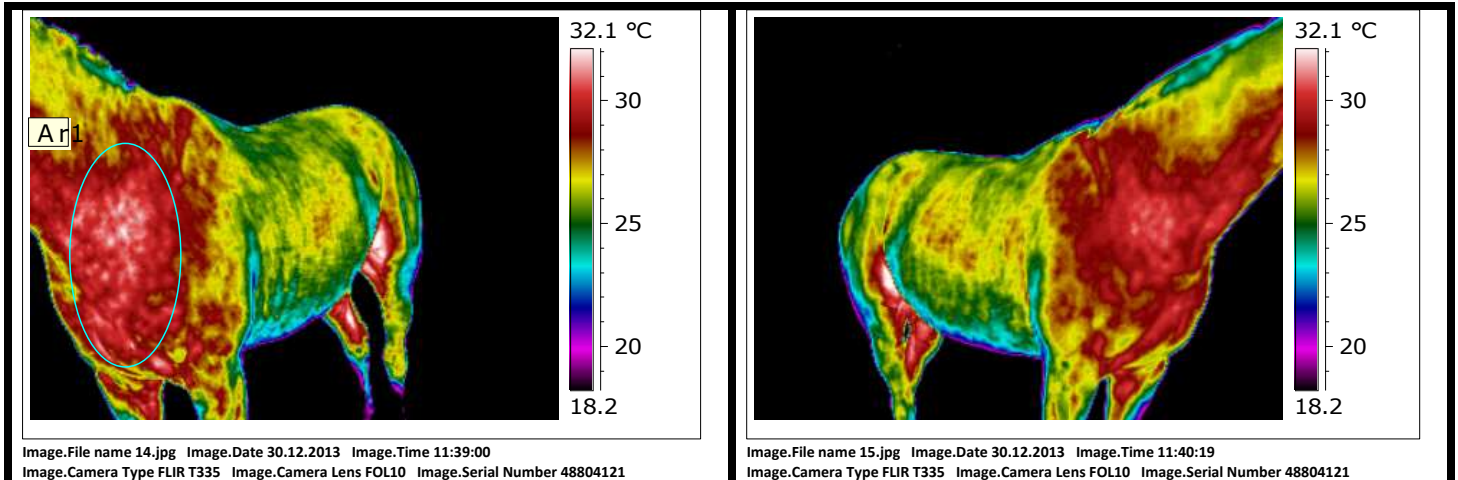


Mild asymmetry over C1-2 with heat greater on the left, lower cervical area heat greater on the left as in above images. Point of shoulder likely represents blanket rub. Palpation including motion palpation recommended for further evaluation of C1-2 for possible chiropractic rotation.

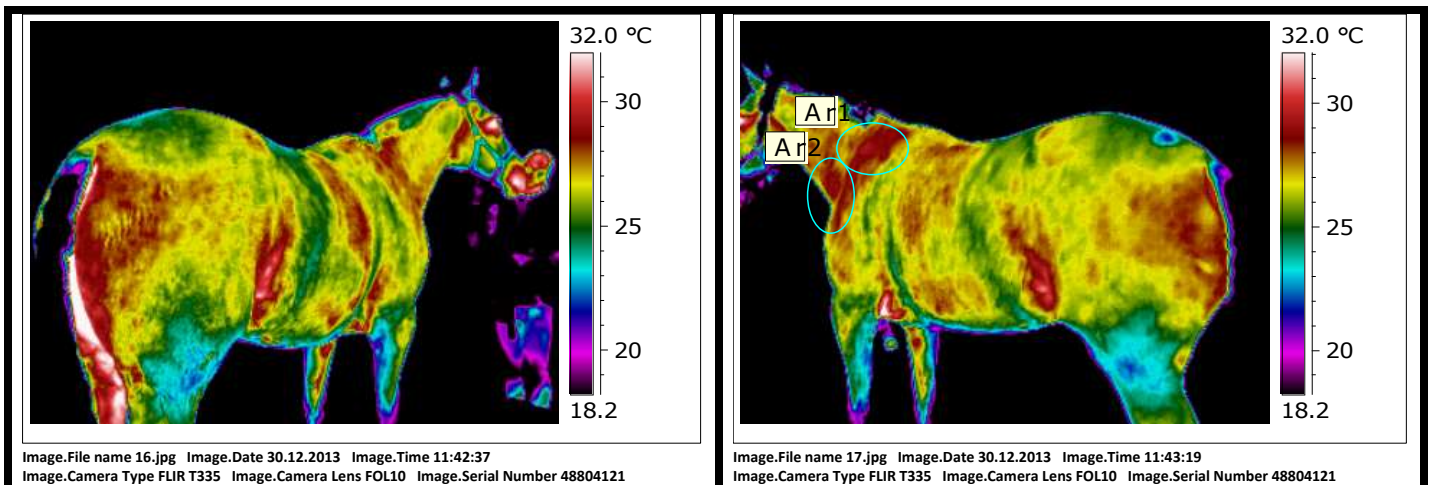
PATIENT: Quarter Champ

THERMOGRAPHY DATE: 30.12.2013

IMAGING TIME: 11.00



Asymmetry in lower cervical/shoulder/chest with heat greater on the left. See comments page 4, images 10/11. Asymmetry along ribs and mid-back looked like possible artifact on previous images but is also visible here therefore would recommend palpation looking for pain/inflammation or could be due to muscular imbalances/uneven limb loading.

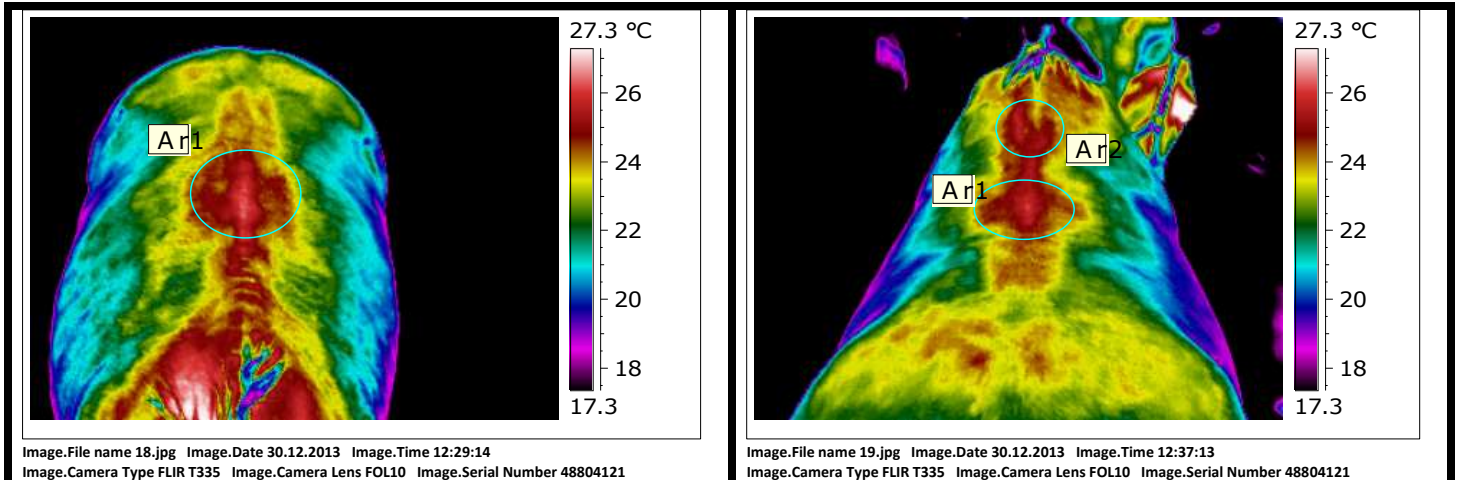


Asymmetry left shoulder/lower neck. See previous comments page 4, images 10/11.

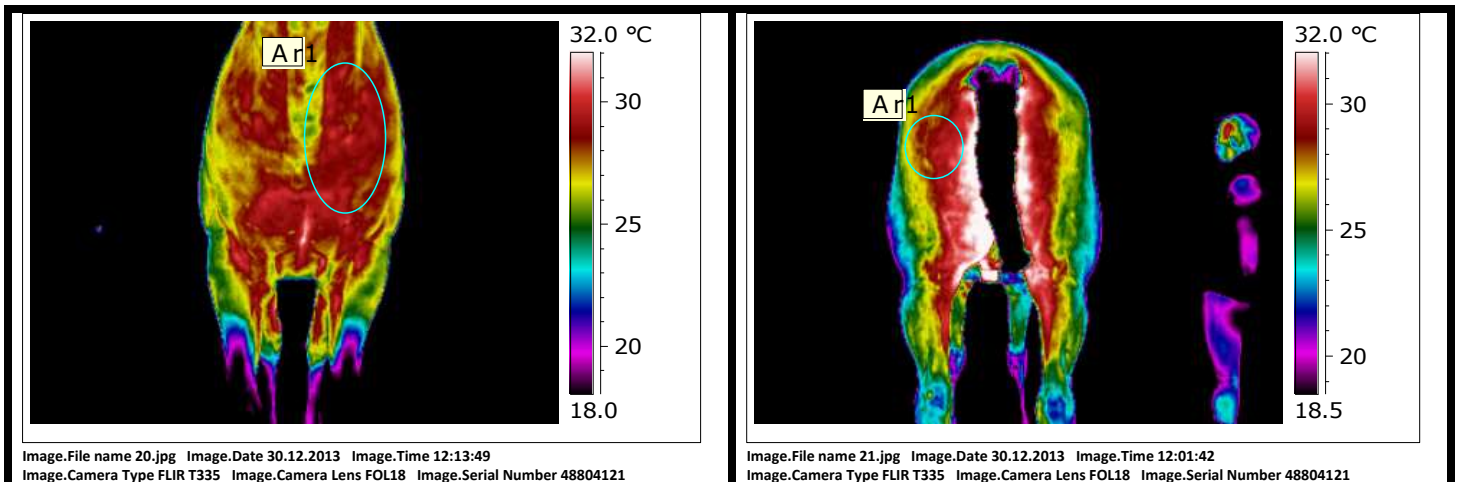
PATIENT: Quarter Champ

THERMOGRAPHY DATE: 30.12.2013

IMAGING TIME: 11.00



Increased heat along thoracic and upper lumbar spine may partially be due to close proximity of dorsal spinous processes to the skin, but the extension into the surrounding soft tissue indicates there is also local inflammation. Chiropractic rotations/fixations and/or saddle fit issues likely present. Palpation, motion palpation and saddle fit analysis recommended for further evaluation.

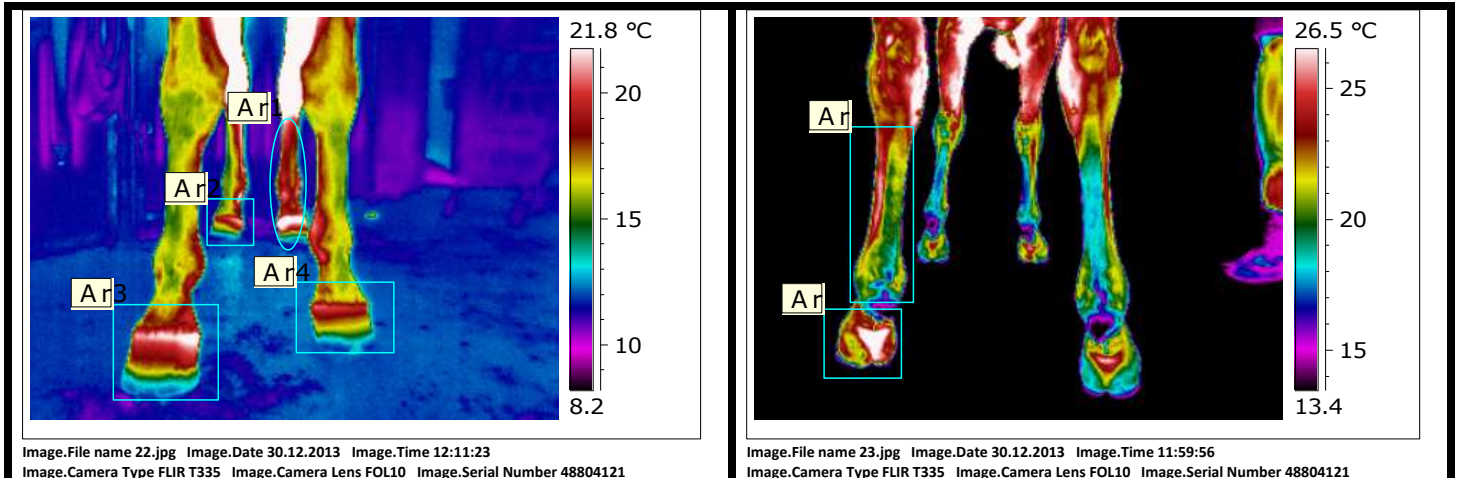


Left chest/shoulder has greater heat than the right. See previous comments page 4, images 10/11. Slightly greater heat left semimembranosus may be artifact but palpation recommended to rule out inflammation.

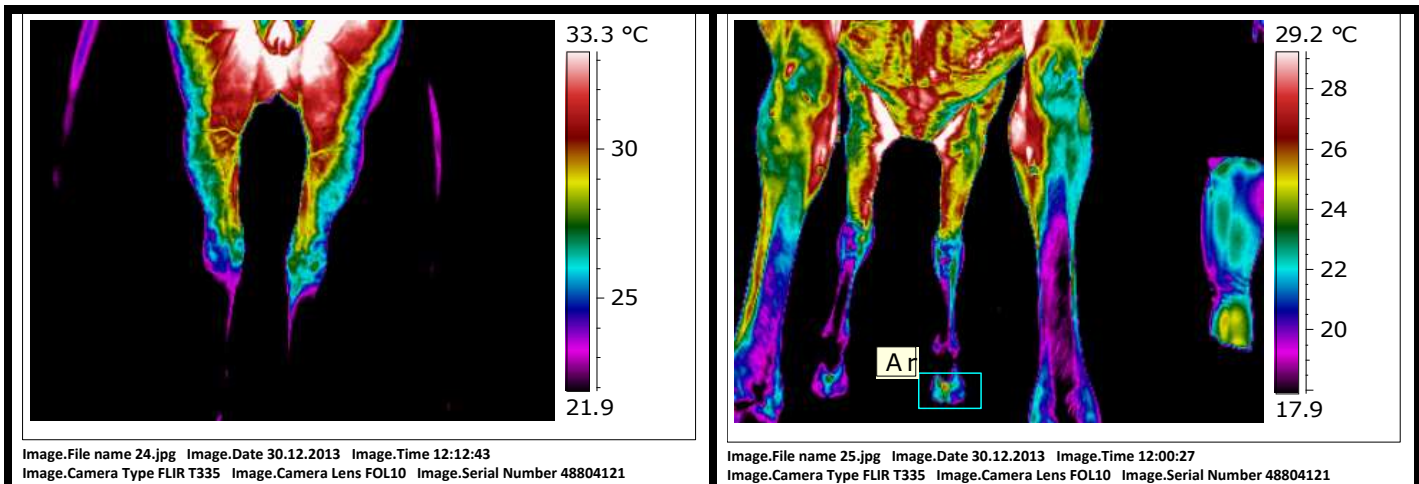
PATIENT: Quarter Champ

THERMOGRAPHY DATE: 30.12.2013

IMAGING TIME: 11.00



Increased heat in the right front and left hind feet. Uneven pressure seen along all four coronary bands with greater pressure seen medially extending into tendons. Increased heat left hind heel and left hind flexor tendons. Gait analysis, posture analysis, hoof tester evaluation and flexion testing may all be useful for further evaluation. Radiographs based on those findings may also be warranted. The increased heat seen in the left hind is likely primary due to hoof inflammation/infection/imbalance but may also be secondary to uneven limb loading or extension of inflammation from lower limb.

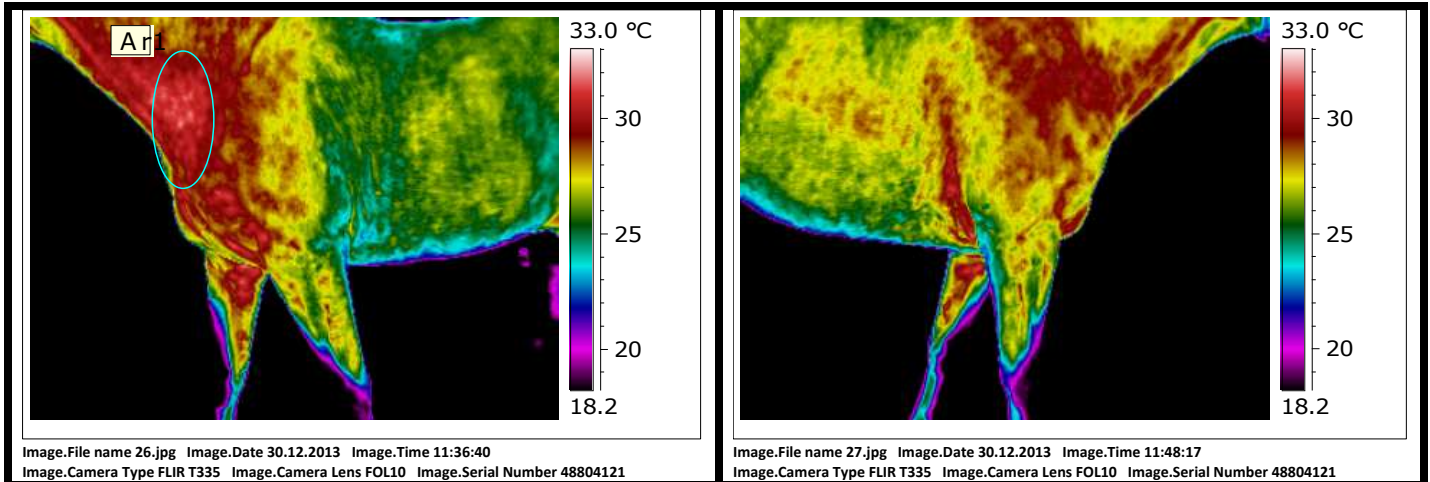


Asymmetry in front feet seen as in previous images.

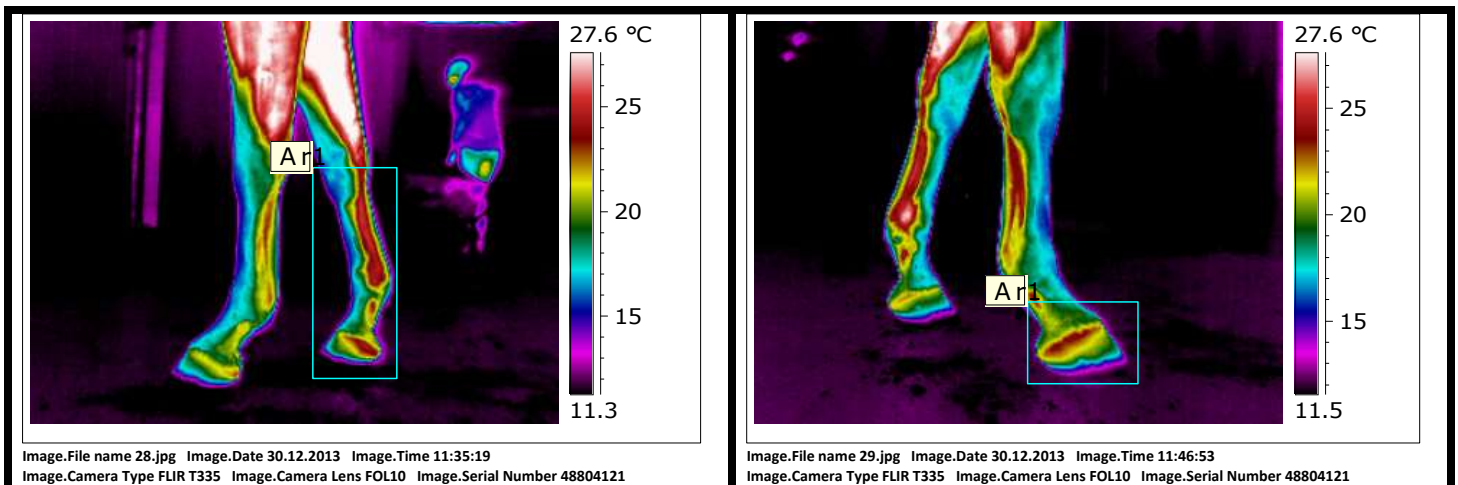
PATIENT: Quarter Champ

THERMOGRAPHY DATE: 30.12.2013

IMAGING TIME: 11.00



Asymmetry in the shoulder/lower cervical area. See previous comments page 4, images 10/11.



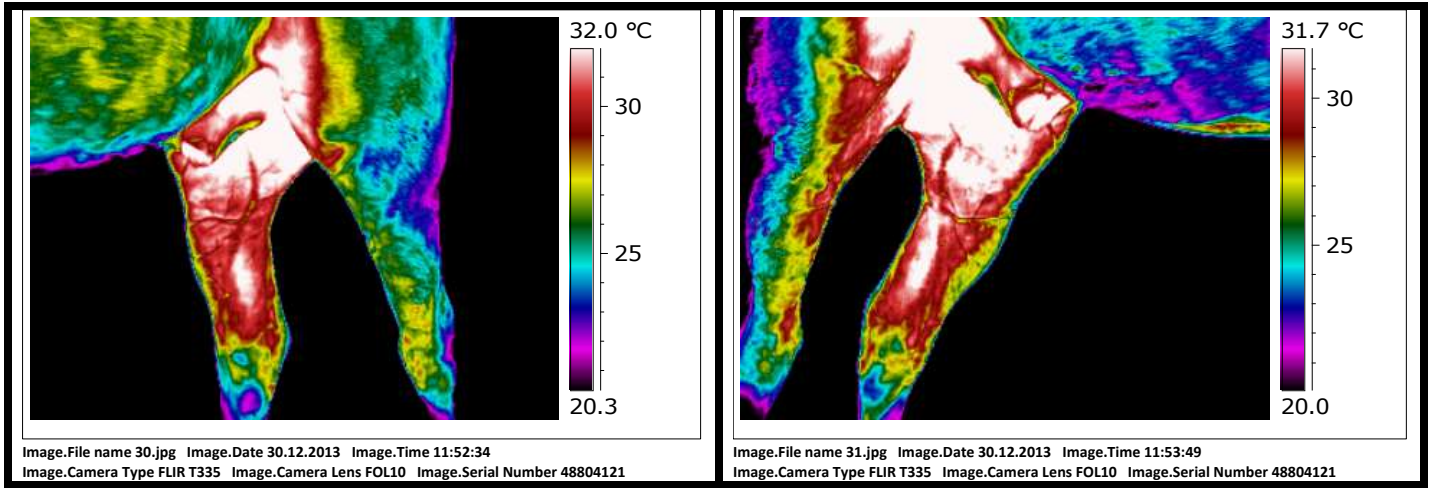
Asymmetry in the front lower limbs/feet again seen with increased heat right front foot and flexor tendons, especially medial tendons. Primary inflammation or off-loading of opposite limb present. Gait analysis, postural analysis, hoof tester evaluation and possible flexion tests recommended.



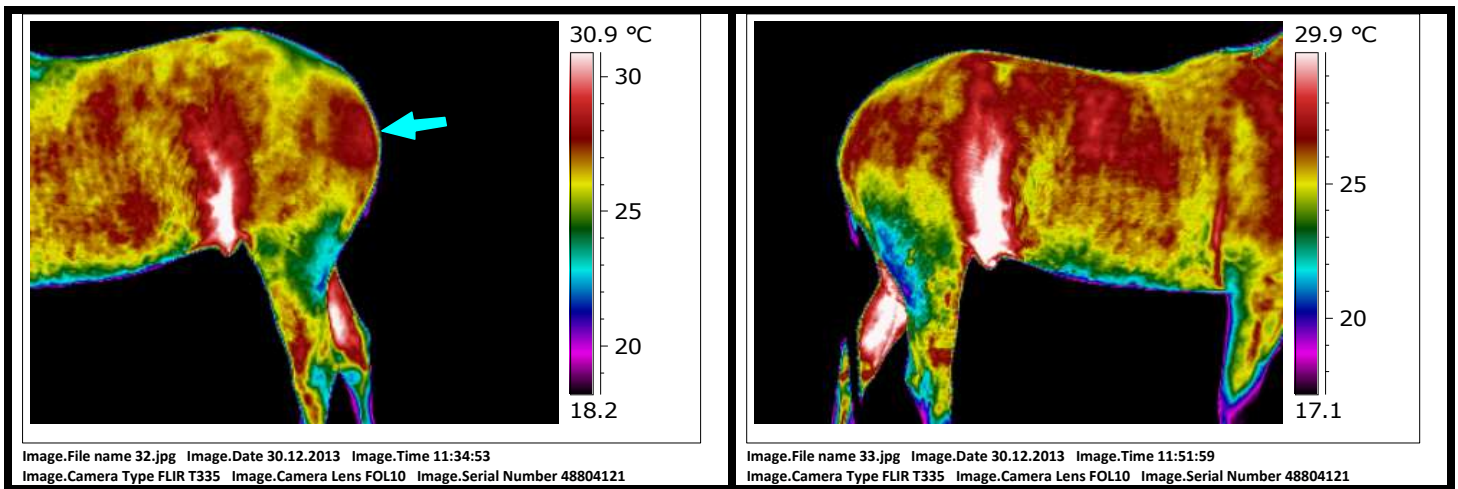
PATIENT: Quarter Champ

THERMOGRAPHY DATE: 30.12.2013

IMAGING TIME: 11.00



**NSF: No Significant Findings**

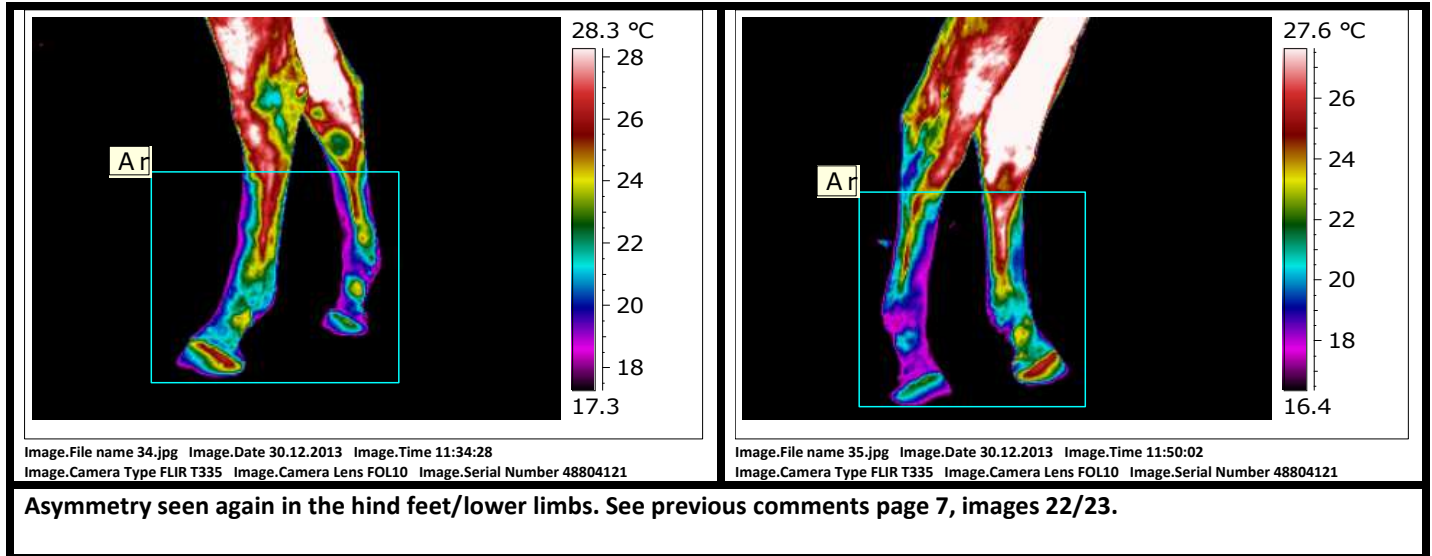


**Increased heat seen on upper left biceps femoris/TFL possible artifact based on digital image but palpation is recommended ruling out local inflammation.**

PATIENT: Quarter Champ

THERMOGRAPHY DATE: 30.12.2013

IMAGING TIME: 11.00



PATIENT: Quarter Champ

THERMOGRAPHY DATE: 30.12.2013

IMAGING TIME: 11.00

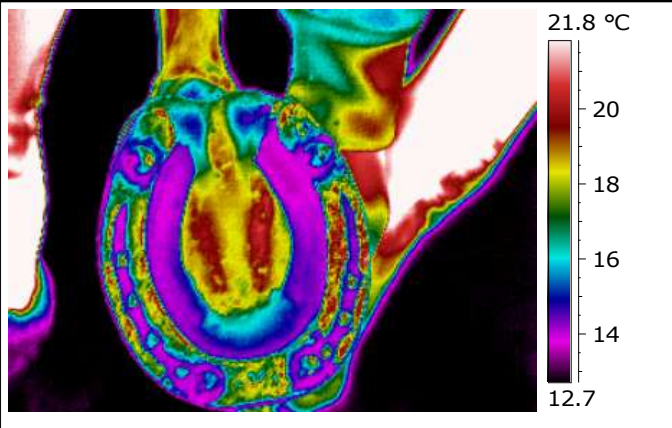


Image.File name 36.jpg Image.Date 30.12.2013 Image.Time 12:39:43  
 Image.Camera Type FLIR T335 Image.Camera Lens FOL10 Image.Serial Number 48804121

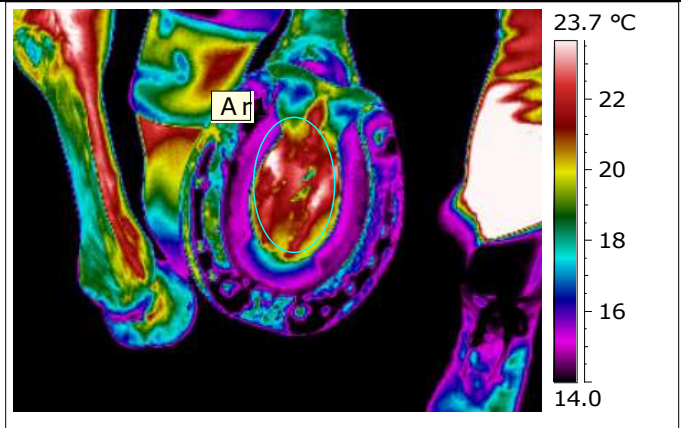


Image.File name 37.jpg Image.Date 30.12.2013 Image.Time 12:40:29  
 Image.Camera Type FLIR T335 Image.Camera Lens FOL10 Image.Serial Number 48804121

Asymmetry seen in feet as in other images with heat greater on the right front. Postural analysis, digital pulse and hoof tester evaluation recommended ruling out primary inflammation versus uneven limb loading.

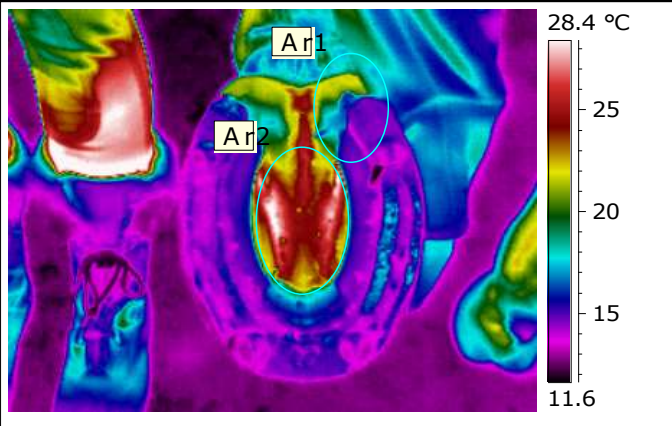


Image.File name 38.jpg Image.Date 30.12.2013 Image.Time 12:42:25  
 Image.Camera Type No camera Image.Camera Lens No lens Image.Serial Number -

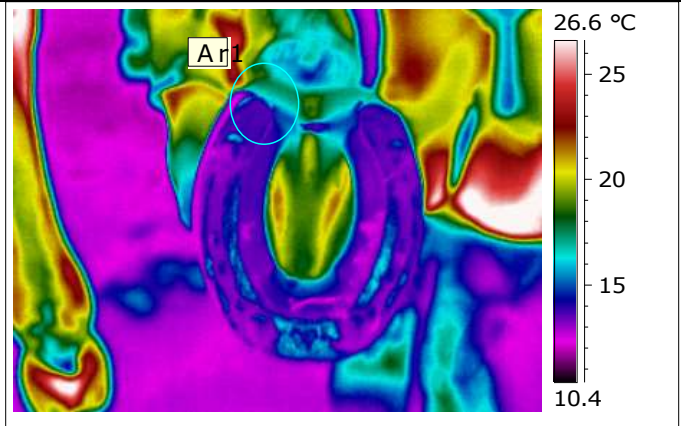


Image.File name 39.jpg Image.Date 30.12.2013 Image.Time 12:41:48  
 Image.Camera Type No camera Image.Camera Lens No lens Image.Serial Number -

Asymmetry again seen in the hind feet with some jamming of the medial heel both hind feet. Uneven heel pressure may be postural or from hoof imbalances. See previous comments on hind feet page 7, images 22/23.



**PATIENT:** Quarter Champ

**THERMOGRAPHY DATE:** 30.12.2013

**IMAGING TIME:** 11.00

**SUMMARY AND RECOMMENDATIONS:** Quarter Champ is a nice looking horse but there are some abnormalities that warrant further evaluation prior to possible purchase.

The asymmetry in the neck/shoulder area and feet are very much a concern. The increased heat seen in the right front may be primary, but more likely is due to off-loading of the left front. Postural analysis, gait analysis and thorough veterinary chiropractic evaluation is recommended for further evaluation of the increased heat in the left C1-2, lower cervical and shoulder areas which may be muscular but likely is due to chiropractic lesions in the area.

The asymmetry in the hind feet is more likely due to primary lesions in the left hind foot/lower limb. The increased heat seen in the left semimembranosus and biceps femoris may be artifact but may also be inflammation – palpation recommended for differentiation. Gait and postural analysis, hoof tester evaluation, digital pulse exam and flexion tests are all useful for further evaluation. History stated there are radiographic changes in the left hind fetlock but other radiographs may also be indicated based on findings from recommended evaluations.

The increased heat in the thoracic and upper lumbar spine warrants thorough veterinary chiropractic evaluation and saddle fit analysis. Correction of both saddle fit issues and vertebral fixations/rotations are likely needed to resolve the inflammation seen and painful areas mentioned in history.

Some imbalances are seen in the feet which may be due to hoof imbalances but may also be due to uneven loading of the foot from issues in the limbs. Thorough visual exam and hoof tester analysis recommended ruling out primary foot issues. Balancing the body and feet together with resolution of any acute inflammation in the joints/tendons/feet will give the best chance for resolution and soundness.

**Thank You!**

Reviewing Veterinarian: Debra K Tibbitts, DVM, CVCP, EDO, CVA, CIT

