

EquiScan **IR**

Equine Thermal Imaging



# Thermal Imaging Report

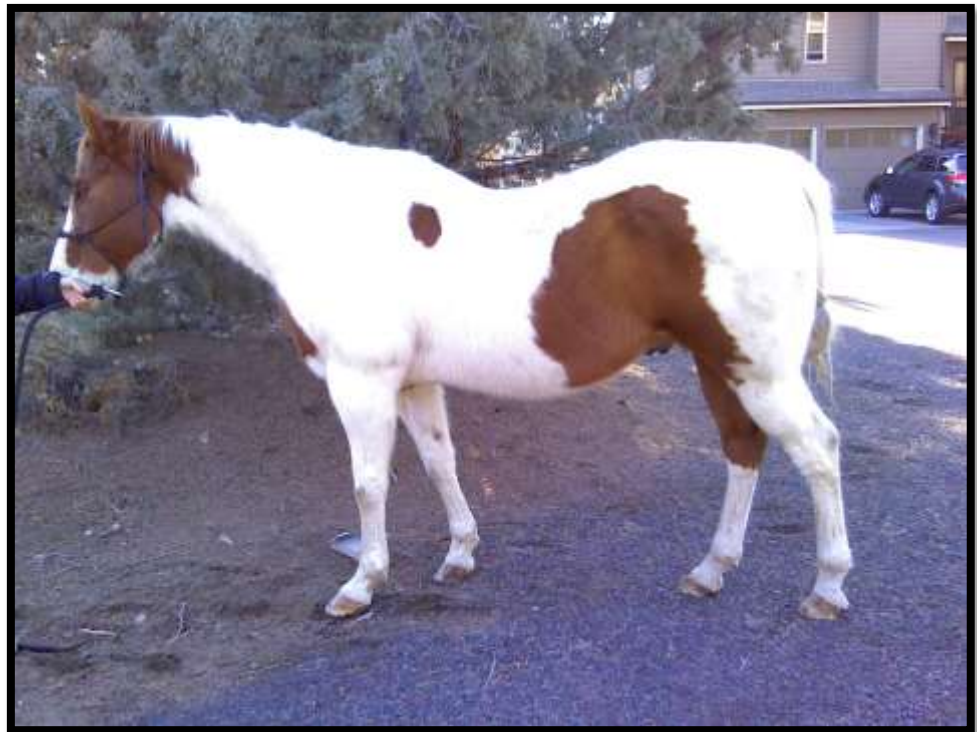## Bo



*Thermal Imaging completed by  
a Certified Thermographer  
Authorized with the EquineIR™  
Network.*



*Interpretative results  
completed by Licensed  
Veterinarians in contract with  
Integrated Equine Infrared.*



**Equiscan IR**

P.O. Box 3500-110 Sisters OR, 97759

PH: 541-550-0514

WEB: [www.equineir.com](http://www.equineir.com)  
EMAIL: [info@equineir.com](mailto:info@equineir.com)



Phone: 541-550-0514  
Email: [equiscanir@gmail.com](mailto:equiscanir@gmail.com)  
[www.equineir.com](http://www.equineir.com)

**PATIENT:** Bo

**THERMOGRAPHY DATE:** Jan 22, 2014

**IMAGING TIME:** 1:00 PM

January 28, 2014

Becky Brunoe  
21711 Los Serranos Dr.  
Bend, OR 97701

Dear Becky Brunoe:

EquineIR was recently requested to perform a full body thermal imaging scan of: **Bo**

The following photo report was completed by your EquineIR™ Certified Thermographer and all interpretative results were channeled through [interpretir.com](http://interpretir.com) and subsequently formulated and input by a licensed veterinary team member with Integrated Equine Infrared.

The interpretation is intended to aid your state-licensed veterinarian in providing a diagnostic or treatment protocol. All follow-up testing and treatments should be conducted and administered by your primary veterinarian. The interpretation provided is based solely on the conditions at the time of survey and the thermal images included in this report. Thermography is a diagnostic tool that measures heat emitted from the surface of the patient. The thermal imaging camera converts infrared energy into a visible image. Emitted heat is related to circulation; as such, the thermal camera can help detect areas of inflammation as well as decreased circulation. Thermal symmetry is key, so you compare one anatomic area with the same area on the other side. The EquineIR™ report is prepared in this manner. It should be understood that correct patient preparation and environment are vital to a successful survey. Your EquineIR™ technician is also a Certified Infrared Thermographer and has been trained in the proper use and the proven techniques of thermal imaging as it is used with horses. There are however certain situations which may reduce the quality of the survey including the improper preparation of the horse prior to technician's arrival. The interpreting veterinarians who review the imagery base their findings and recommendations on information provided, so it is critical that proper care be taken in the preparation process to ensure success.

Thermal imaging is a physiologic modality and should not be relied upon as the sole diagnostic tool. A complete clinical examination by your state-licensed veterinarian is always recommended for the best diagnosis and follow-up treatment. This Report is not a definitive diagnosis of any illness or disease. It is intended for use only by licensed veterinary professionals to evaluate patient health, diagnose medical conditions, and provide treatment. It is not to be used by individuals for self-diagnosis or self-evaluation, nor for the diagnosis or evaluation of other non-qualified personnel. This report does not replace, nor is intended to replace a complete clinical evaluation by your state-licensed veterinarian. Under no circumstances will EquineIR™, Integrated Equine Infrared or its affiliates be held responsible for illness, injury, or death to the patient as a result of the information contained herein. This report does not replace, nor is intended to replace a complete clinical evaluation.

Your EquineIR™ Technician looks forward to working with you in the future. If you would like to set up an ongoing maintenance imaging program for your horse(s), we can arrange this at discounted rates along with multiple horse discounts. Please call our office with any questions as we would love to assist you in your success.

Sincerely,

*Courteney Satko*

Courteney Satko, *Certified Infrared Thermographer #9473*  
EquiScanIR

**PATIENT:** Bo

**THERMOGRAPHY DATE:** Jan 22, 2014

**IMAGING TIME:** 1:00 PM

## EQUINE CLIENT INFORMATION

**CLIENT NAME:** Becky Brunoe  
**MAILING ADDRESS:** 21711 Los Serranos Dr., Bend, OR 97701  
**CLIENT EMAIL:** becky@bendproperty.com  
**CLIENT PHONE:** 541-350-4772

**HORSE AGE:** 20  
**HORSE BREED:** Paint  
**HORSE PRIMARY USE:** Trail, Western

## SURVEY INFORMATION

**THERMOGRAPHER:** Courteney Satko  
**INFRARED CERTIFICATION #:** 9473  
**INFRARED CAMERA MODEL:** FLIR T420      **CAMERA SERIAL NUMBER:**  
**NUMBER OF THERMAL IMAGES SUBMITTED:** 30

**WEATHER:** Calm, Cloudy  
**APPROXIMATE TEMPERATURE:** 45 °F  
**IMAGING LOCATION:** Outside in shade

**EXERCISED PRIOR:** Yes    **HOW LONG:** 20 minutes    **WHEN:** 30 minutes prior to scan  
**TYPE OF EXERCISE:** Walk, Jog ,Trot

**BOOTS OR WRAPS ON HORSE?** No      **HOURS SINCE:** 1  
**FLYSpray OR LINIMENTS APPLIED WITHIN 24 HOURS:** No

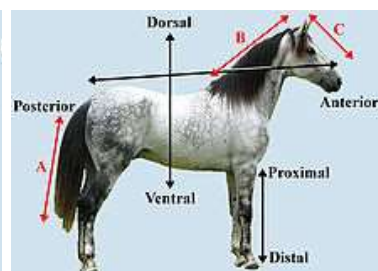
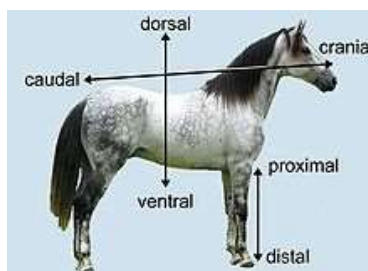
**REASON FOR SCAN or HISTORY RECEIVED:** Hind leg suspected injury/soreness. Started having issues with his hind leg about a year ago. Left back leg is the leg suspected of injury due to drastic and continuous tripping during mild exercise. Recently he has started to buck and show signs of pain and the bucking is very out of character for this horse making the owner push for a scan. When he stands, he always has his hip cocked on the right hind with no weight on the left. Current vet has put him on anti-inflammatory. Three years ago Bo fell on ice on the drive way on his left side, which has led the owner to believe that was part of the cause of the injury. Bo has a winter coat and also was unable to be hauled to another location due to vet and owner discretion.

## INTERPRETATION INFORMATION (Completed by Veterinarian)

**INTERPRETATION TYPE:** Full Enhanced Survey

**DATE OF INTERPRETATION:** 1/28/2014

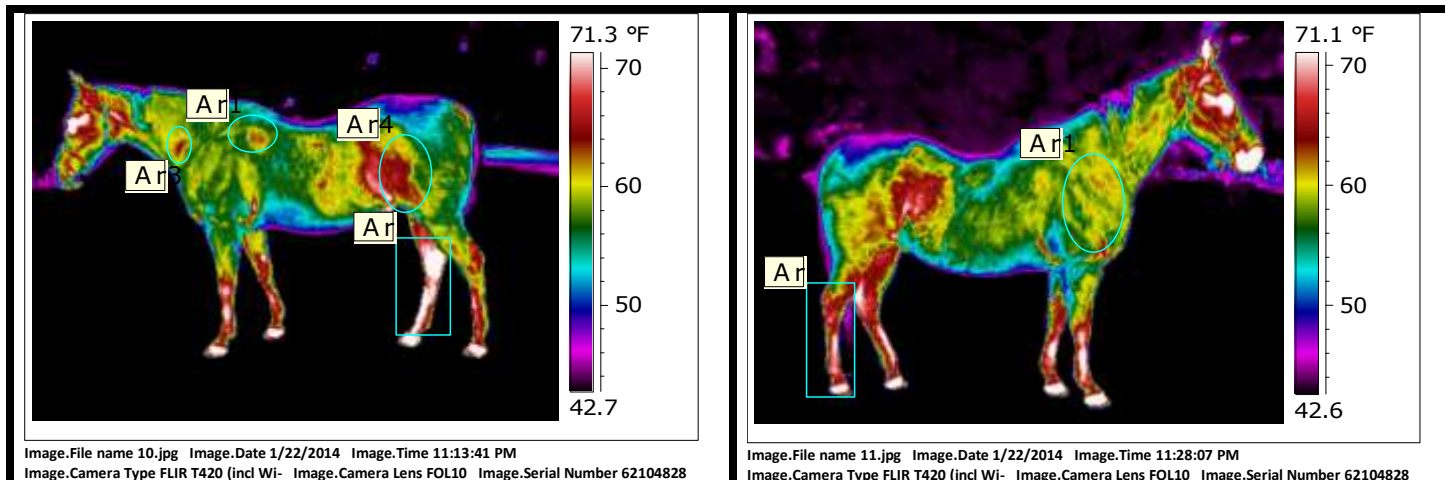
**REVIEWING VETERINARIAN:** Dr. Debra K Tibbitts



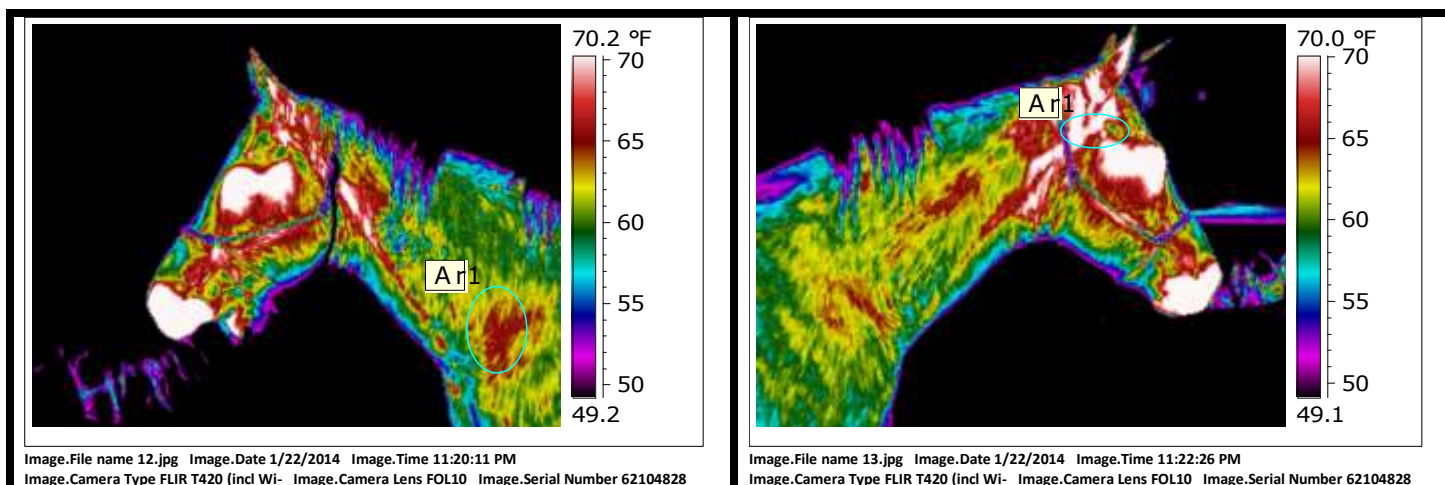
PATIENT: Bo

THERMOGRAPHY DATE: Jan 22, 2014

IMAGING TIME: 1:00 PM



There is some asymmetry on the lateral views, though some may be due to his color pattern. Ar1 on both sides is an area of color which could account for the increased areas of heat. There is asymmetry in the lower hind limbs, heat being greater on the right, which may partially be due to color pattern but also likely due to off-loading of the left hind. There is asymmetry within the left hind with decreased heat in the biceps femoris but increased heat at the stifle. Palpation, motion palpation, stress tests and flexion tests recommended checking for stifle inflammation/pain/instability. Small focal area of increased heat at base of left neck. Palpation recommended checking for local inflammation.

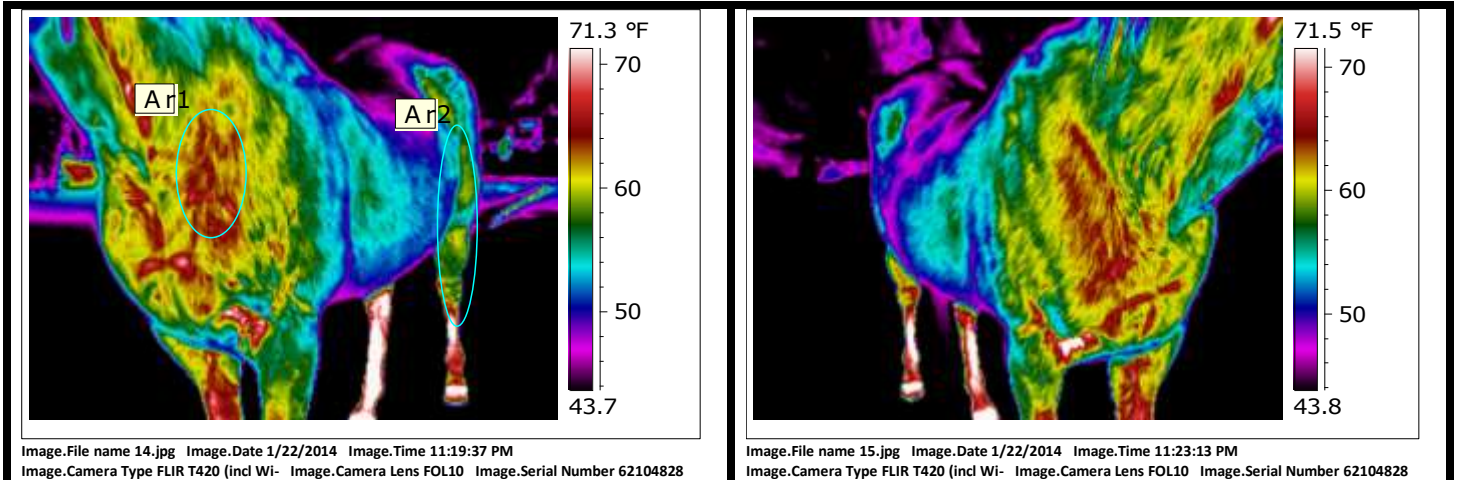


Asymmetry seen left base of neck. See previous comments. There also appears to be some asymmetry at the TMJ to the atlas with heat greater on the left. Palpation of the area and a thorough dental evaluation via speculum exam are recommended.

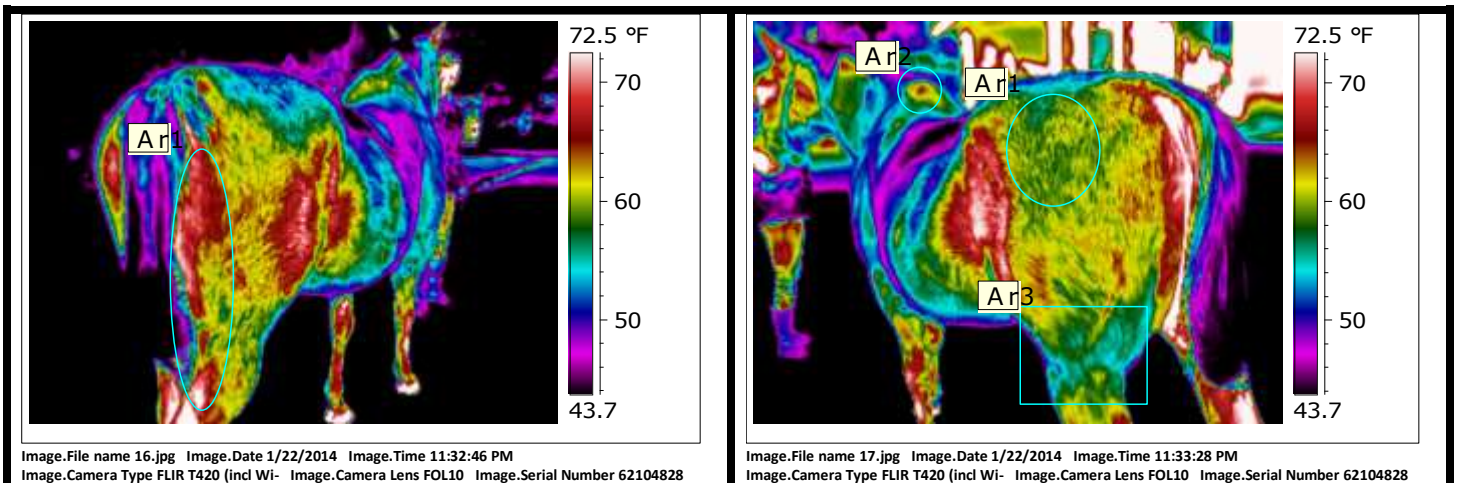
PATIENT: Bo

THERMOGRAPHY DATE: Jan 22, 2014

IMAGING TIME: 1:00 PM



Slight asymmetry in the chest/shoulder with heat greater on the left. Asymmetry in the hind limbs with left hind cooler than right. Both asymmetries likely due to off-loading of the left hind limb. Palpation of the left shoulder/lower neck area still recommended ruling out local inflammation.

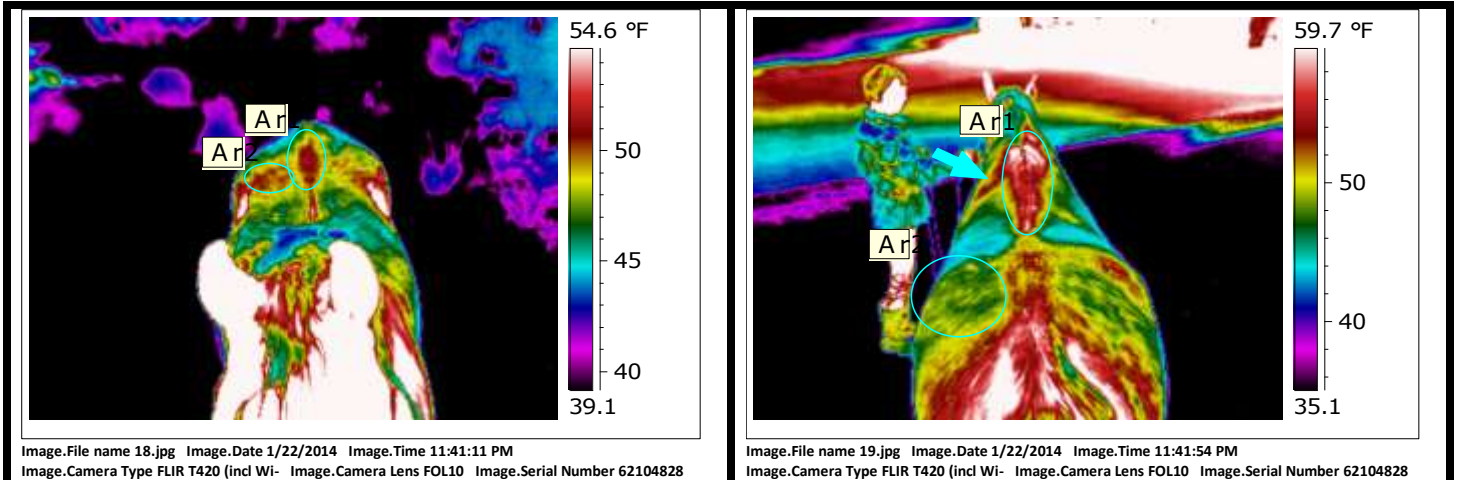


Asymmetry in the hindquarters with heat greater on the right hind semimembranosus and gastrocnemius. Cool area around gastrocnemiums and proximal tibia. This may be due to off-loading of the left hind or nerve or circulatory disturbance in the area. Palpation and motion palpation recommended. There is also a focal area of increased heat at the top of the withers which may be superficial due to a rub or irritation from blanket/pad.

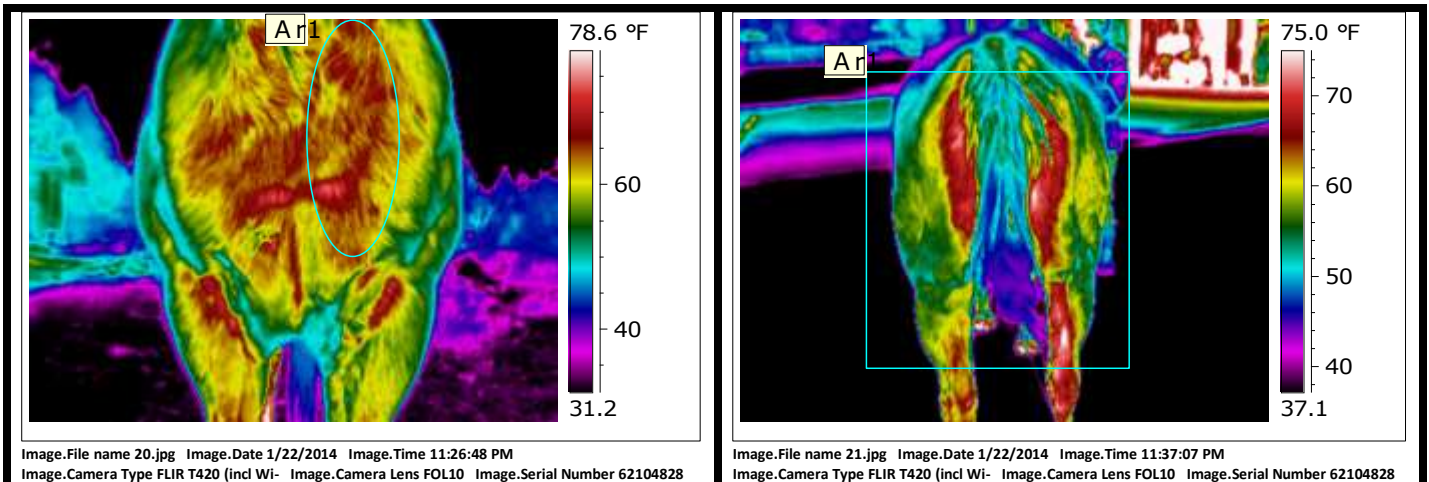
PATIENT: Bo

THERMOGRAPHY DATE: Jan 22, 2014

IMAGING TIME: 1:00 PM



Increased heat along sacrum which may be due to conformation but local palpation and motion recommended checking for inflammation and proper motion. Asymmetry in the gluteal muscles with heat greater on the right likely due to off-loading of the left hind limb. Increased heat along withers and thoracic spine is at least partially due to close proximity of the dorsal spinous processes to the skin but may also be due to saddle fit issues or chiropractic lesions. Motion palpation and saddle fit analysis recommended for further evaluation. There is also asymmetry at the shoulder with heat greater on the left and the left shoulder appears larger. This may be due to off-loading, horse being dominant on the left causing uneven shoulder development but local palpation recommended checking for inflammation/proper mobility.

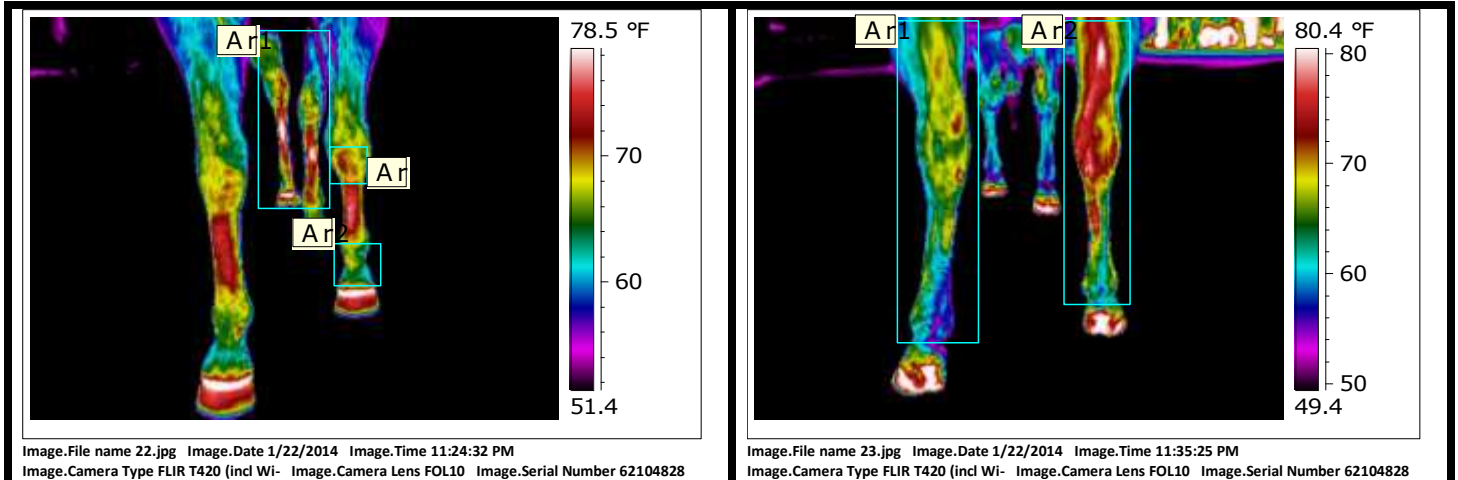


Asymmetry seen in chest and hindquarters. See previous comments page 5, images 14/15 and images 16/17.

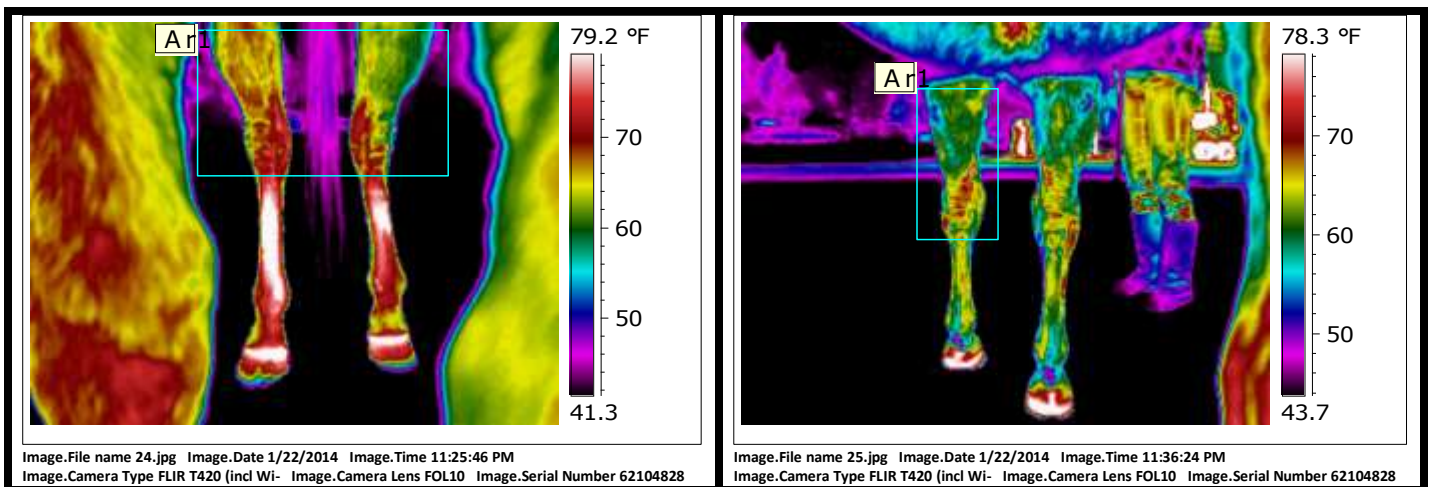
PATIENT: Bo

THERMOGRAPHY DATE: Jan 22, 2014

IMAGING TIME: 1:00 PM



**Asymmetry in the hind limbs, with heat generally greater on the right. Off-loading most likely cause. There is also patterning over the hock that is suggestive of tarsitis in both hind limbs. Palpation, motion palpation and possibly radiographs based on findings. (Flexion tests normally recommended but not likely to be able to be performed successfully in this case.) There is also slight asymmetry in the front limbs with heat slightly greater on the left which may be secondary to off-loading of the left hind but palpation recommended ruling out a primary inflammation.**

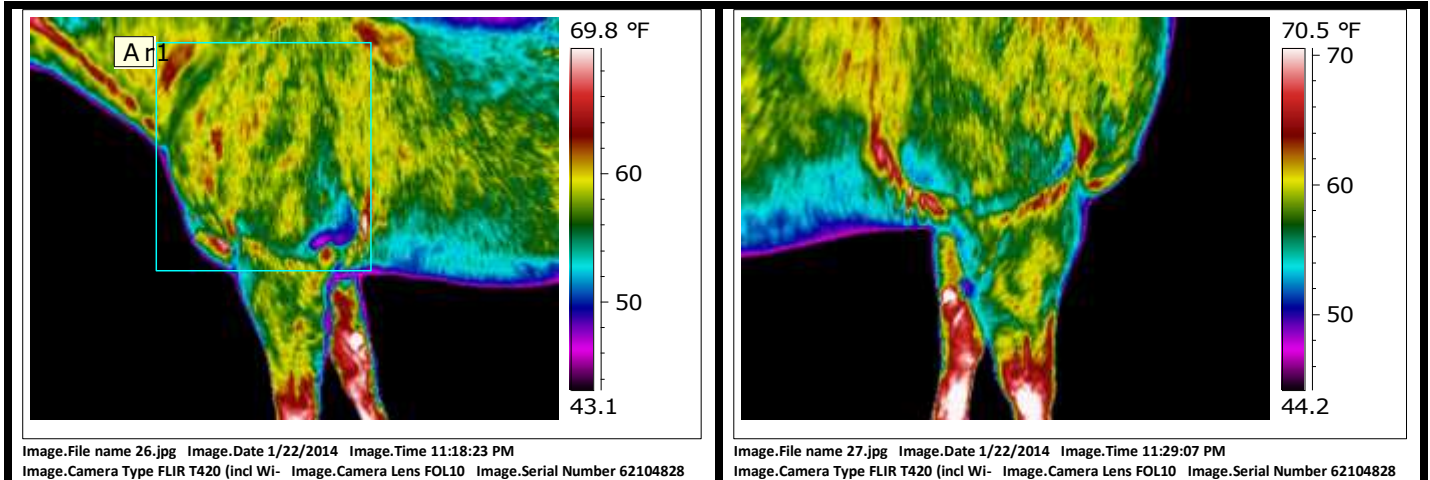


**Asymmetry in hind and front limbs. See previous comments this page.**

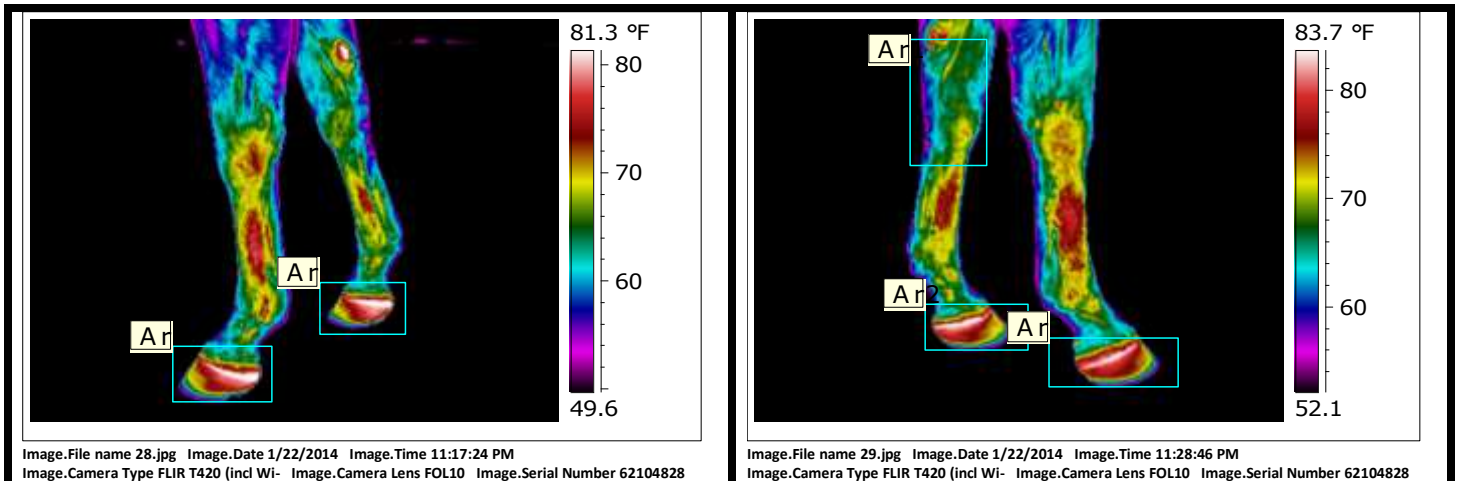
PATIENT: Bo

THERMOGRAPHY DATE: Jan 22, 2014

IMAGING TIME: 1:00 PM



Mild asymmetry shoulder area. See previous comments page 5, images 14/15.



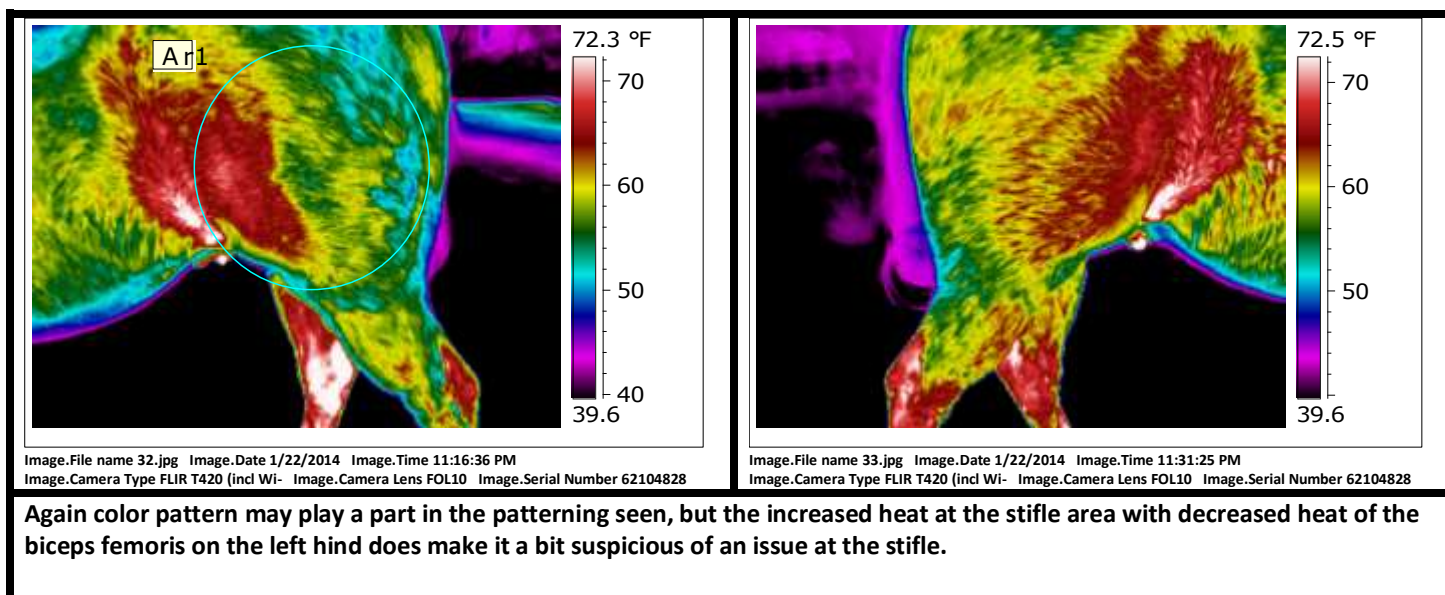
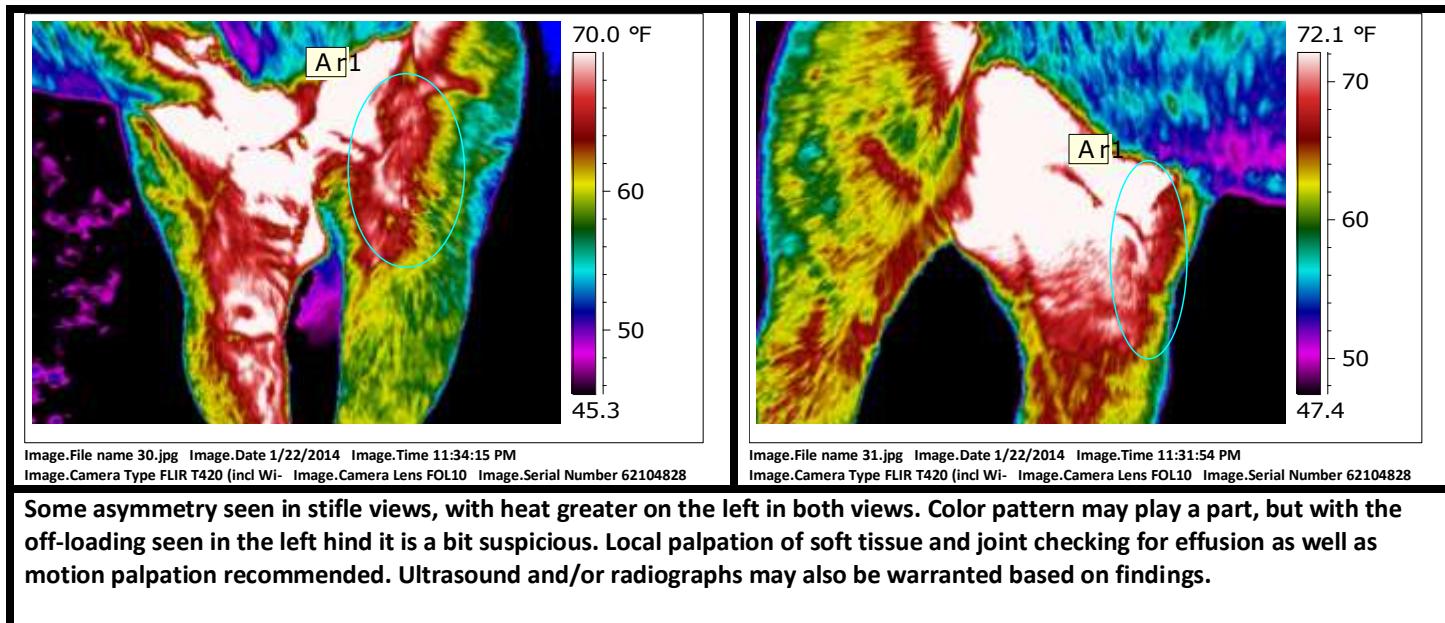
Slight asymmetry front limbs with heat slightly greater left medial forelimb. Likely due to off-loading of the left hind. There is increased heat both front feet at the heels which may indicate hoof imbalances.



PATIENT: Bo

THERMOGRAPHY DATE: Jan 22, 2014

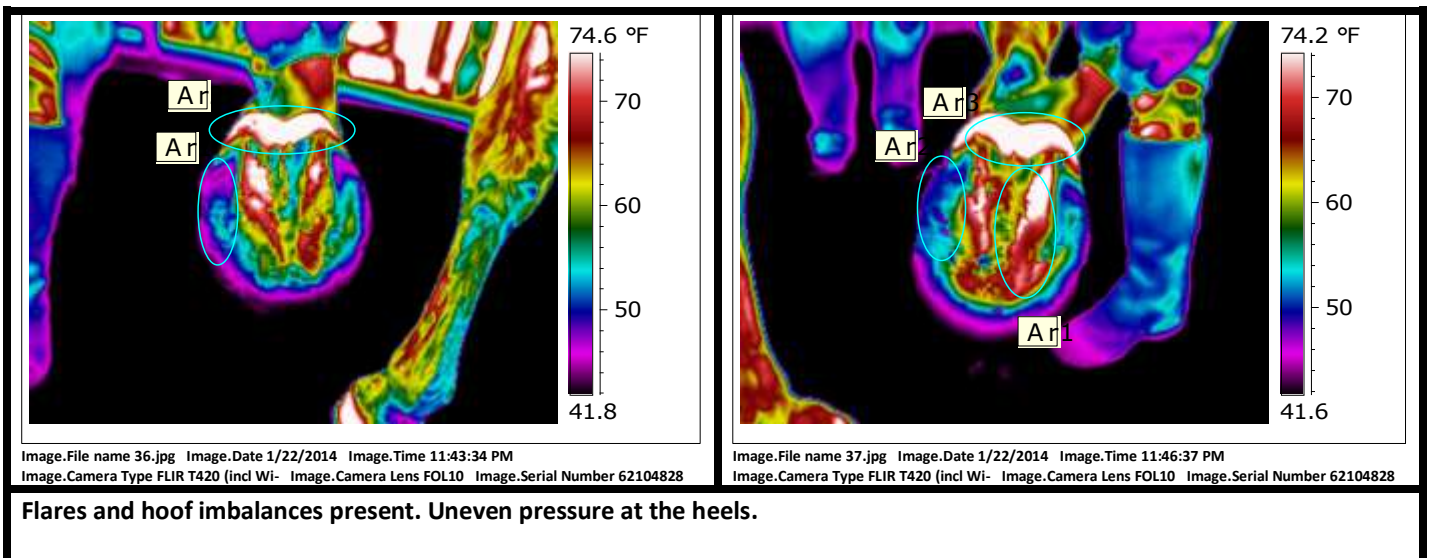
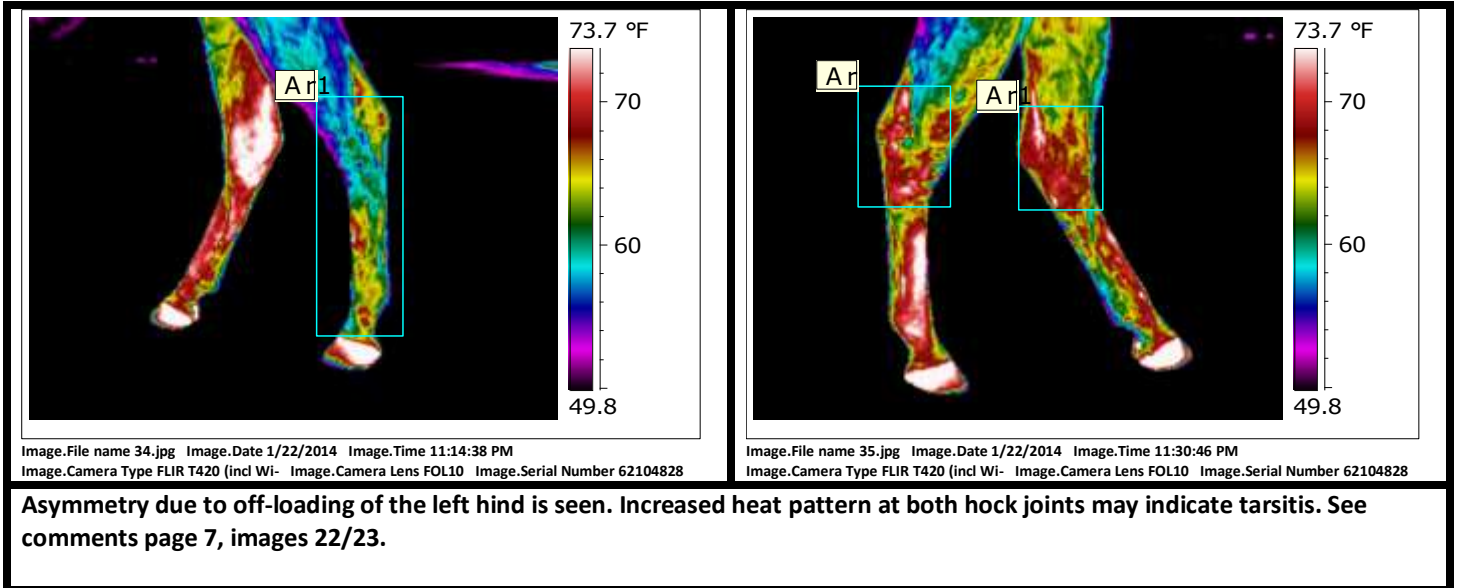
IMAGING TIME: 1:00 PM



PATIENT: Bo

THERMOGRAPHY DATE: Jan 22, 2014

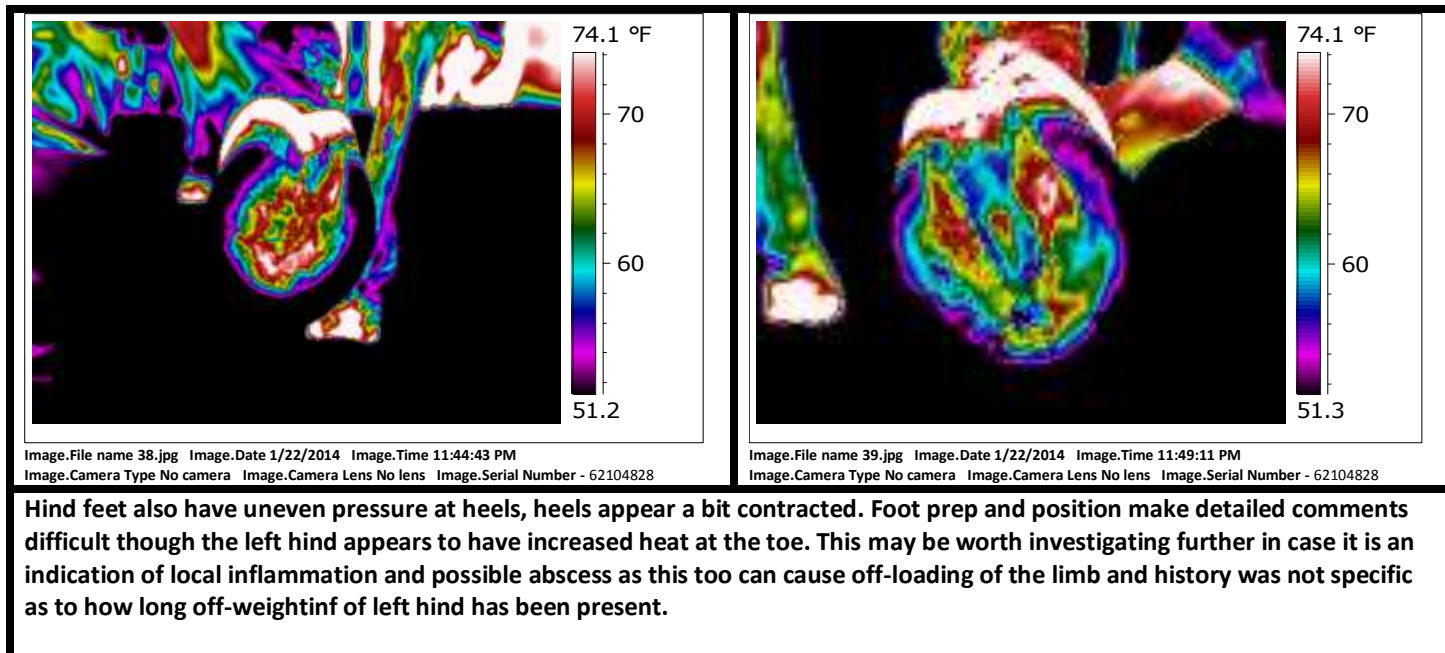
IMAGING TIME: 1:00 PM



PATIENT: Bo

THERMOGRAPHY DATE: Jan 22, 2014

IMAGING TIME: 1:00 PM



**PATIENT:** Bo

**THERMOGRAPHY DATE:** Jan 22, 2014

**IMAGING TIME:** 1:00 PM

**SUMMARY AND RECOMMENDATIONS:** Bo looks like a sweet boy and his thermal images show some areas of concern to investigate further.

There are some issues that come from the different hair colors having different thermal properties and it is also noted in the history that boots or wraps had been on an hour prior to imaging. This can cause artifacts on the lower limbs.

The off-loading of the left hind limb is likely responsible for the decreased heat over areas of the left hind limb and generalized increase of heat in the right hind limb. It also is likely a factor in the increased heat in the left front limb.

There is increased heat in the left lower neck/shoulder area which may indicate local inflammation/muscular strain/chiropractic issue. There is asymmetry at the TMJ with the right side having increased heat from TMJ to atlas. Dental problems should be ruled out via thorough oral speculum examination. There may also be primary inflammation in the TMJ joint and surrounding tissue. Palpation, motion palpation and veterinary chiropractic examination recommended.

Both hocks have a thermal pattern suggestive of tarsitis. Palpation, motion palpation, flexion tests if possible and radiographs based on findings are all helpful for further evaluation. The left stifle has some increased heat that warrants further investigation through palpation, motion palpation and stress tests of the patellar ligaments. Radiographs and/or ultrasound may also be warranted based on exam findings.

There is increased heat along the thoracic spine, withers and sacrum which may partially be due to conformation and close proximity of the spine to the skin. But there may also be inflammation present. Palpation recommended to rule out chiropractic issues. There is an uneven pattern along the ribs suggesting muscle imbalances from uneven limb loading.

There is increased heat at the heels of all four feet. Imbalances and flares are present in all four feet. Proper hoof balance is important for both short and long-term soundness. The left hind foot has an area of increased heat at the toe which should be investigated further to rule out a hoof abscess. If there is a hoof abscess present it could cause the horse to off-load the left hind limb.

**Thank You!**

Reviewing Veterinarian: Debra K Tibbitts, DVM ,CVCP, EDO, CVA, CIT

